

REVIEW ARTICLE

Emerging and New Treatment Options for Knee Osteoarthritis

Md. Abu Bakar Siddiq^{1,2,*}, Danny Clegg³, Tim L. Jansen⁴ and Johannes J. Rasker⁵

¹Department of Physical Medicine and Rheumatology, Brahmanbaria Medical College, Brahmanbaria, Bangladesh; ²School of Health Sport and Professional Practice, University of South Wales, Pontypridd, United Kingdom; ³School of Health and Social Care, London South Bank University, London, United Kingdom; ⁴Department of Rheumatology, Viecuri MC, Venlo, The Netherlands; ⁵Faculty of Behavioral, Management and Social Sciences, Department Psychology, Health and Technology, University of Twente, Enschede, The Netherlands

Abstract: Osteoarthritis (OA) is the most prevalent type of arthritis worldwide, resulting in pain and often chronic disability and a significant burden on healthcare systems globally. Non-steroidal anti-inflammatory drugs (NSAIDs), analgesics, intra-articular corticosteroid injections are of little value in the long term, and opioids may have ominous consequences. Radiotherapy of knee OA has no added value. Physical therapy, exercises, weight loss, and lifestyle modifications may give pain relief, improve physical functioning and quality of life. However, none of them has articular cartilage regenerating potential. Due to a better understanding of osteoarthritis, innovative new treatment options have been developed. In this narrative review, we focus on emerging OA knee treatments, relieving symptoms, and regenerating damaged articular cartilage that includes intra-articular human serum albumin, conventional disease-modifying anti-rheumatic drugs (DMARDs), metformin, lipid-lowering agents (statin), nerve growth factors antagonists, bone morphogenetic protein, fibroblast growth factors, Platelet-Rich Plasma (PRP), Mesenchymal Stem Cells (MSC), exosomes, interleukin-1 blockers, gene-based therapy, and bisphosphonate.

ARTICLE HISTORY

Received: January 31, 2021
Revised: June 15, 2021
Accepted: August 30, 2021

DOI:
[10.2174/1573397117666211116111738](https://doi.org/10.2174/1573397117666211116111738)

Keywords: Anti-inflammatory agents, analgesics, cartilage, knee, nerve growth factors, osteoarthritis, pain, platelet-rich plasma.

1. INTRODUCTION

Until the 1990s, osteoarthritis (OA) was considered a “wear and tear” disease resulting in loss of cartilage [1]. New insights in molecular biology have profoundly modified this paradigm [1]. OA is a total joint disease characterized by loss of cartilage, subchondral bone changes, synovitis, and meniscus degeneration [2]. Chemical mediators like cytokines or prostaglandins yielded from synovial fluid and tissue due to increased production of Matrix Metalloproteinases (MMP) by chondrocytes, synoviocytes, and fibroblasts favor the “inflammatory” theory of OA [1, 2]. Over the last three decades, researchers’ continuous efforts to unveil and understand the pathophysiology of Early OA (EOA) in greater detail have enabled us to understand more, recognize the condition, and intervene at its earlier stages. More treatment options are becoming available, slowing or halting disease progression, thereby minimizing disability attributed to the ailment [2].

OA is the most common rheumatic condition, classically associated with people over 65 years of age, but also those

in the 5th and 6th decade of life often experience pain and loss of function in weight-bearing spinal and peripheral joints and non-weight-bearing small joints of the hands [3]. The disease burden for the OA patient is similar to that in rheumatoid arthritis (RA) at the initial visit to a rheumatology clinic and greater after six months [4], so diagnosing early cases can plunge disability prevalence.

Histologically, based on the *Osteoarthritis Research Society International (OARSI) scoring system*, EOA changes have been found only to affect the superficial and middle zones of articular cartilage [2]. Luyten *et al.* proposed classification criteria for knee EOA based on symptoms (pain: at least two episodes for ten days in the past year), radiological changes (Kellgren-Lawrence KL, grade 0 or 1-2 osteophytes only), and early degenerative changes detected by new imaging techniques and arthroscopy [5]. OA is not a joint disease of mere cartilage degeneration. OA also involves meniscus degeneration, subchondral bone change, and synovial membrane thickening [2, 5]. Magnetic Resonance Imaging (MRI) depicted hyperintense subchondral bone marrow also correlates with micro-damage of the trabecular bone histologically and contributes to bone pain. These lesions connect to the accelerated loss of the articular cartilage vicinity and contribute to joint pain and disability, as seen in early and advanced knee OA. Growing evidence suggests Knee OA is both cartilage and bone-based disease [6, 7]. Therefore, en-

*Address correspondence to this author at the Department of Physical Medicine and Rheumatology, Brahmanbaria Medical College, Brahmanbaria, Bangladesh and School of Health Sport and Professional Practice, University of South Wales, Pontypridd, United Kingdom; E-mail: abusiddiq37@yahoo.com

suring maximum benefit from any treatment strategy requires diagnosing and treating OA at its earliest stage, preferably at the modifiable “pre-osteoarthritis” stage [8].

Conventionally, OA is treated with non-pharmacological and pharmacological methods, and their appropriate use could reduce knee replacement incidence [9]. However, there is no uniform measure of success regarding how well different patients respond to treatment strategies. Comparative treatment outcomes are often unequal in terms of effectiveness across different subtypes of OA and or in various stages of the same OA. Perhaps most importantly, some of the treatments are currently not recommended by the National Institute for Health and Care Excellence (NICE) and the American College of Rheumatology (ACR) [10]; hence innovative new treatment options to more effectively managing the disease are warranted [10].

Over the last decades, effective new treatment options and strategies have become available for OA, primarily from pre-clinical and clinical trials [11]. However, one cannot recommend treatment strategies based on a single trial or very few trials only, specifically when the sample populations included in clinical trials are due to inclusion - and exclusion criteria, not truly reflecting patients encountered in routine practice. Therefore, reviewing and updating the evidence supporting effective treatment strategies is indicated. A further pitfall is that regression to the mean in not well-powered designs can bias study results in OA, where we know the placebo effect can be substantial [12]. On the other hand, sham interventions with negative connotations and unpleasant encounters with health care professionals may harm a phenomenon called the nocebo effect [13].

We researched the literature using PubMed and PubMed Central, Google with keywords: Osteoarthritis, knee, treatments, pharmacological, innovative, cartilage enhancement, and looked for specific topics as mentioned in the subheadings of the findings section. Only English language articles were included. Excluded were complementary medicine, alternative medicine, supplements, herbs, diets, surgery. No exclusion was applied based on publication dates; however, considerable emphasis was focused on the most relevant and up-to-date information available at the time of this review. This narrative review evaluates the current and emerging treatment options for OA knee. We aim to synthesize this information to benefit the science and healthcare community.

2. DISCUSSION

Previously published works in the English language that addressed promising treatment options for OA knee (based on both clinical and preclinical trials), for example, Intra-Articular (IA) low-molecular-weight human serum albumin, Disease-Modifying Anti-Rheumatic Drugs (DMARDs), lipid-lowering agents (statin), Nerve Growth Factors (NGFs) antagonists, Bone Morphogenetic Proteins (BMPs), Fi-

broblast Growth Factors (FGFs), interleukin-1 (IL-1) inhibitors (Table 1) are included in this new synthesis. The present article also focuses on regenerative therapies, including Mesenchymal Stem Cells (MSCs), Platelet-Rich Plasma (PRP), MSC-based exosomes, gene therapy, and bisphosphonate therapy to be useful in the disorder (Table 1). As the purpose of the report is to provide a review, we aim to describe promising treatment options in OA-knee rather than focusing on determining a particular approach to managing the disorder.

For easy-going, we discuss the OA-knee emerging interventions into the following six categories: anti-catabolic, anabolic, anti-catabolic and anabolic, interleukin-1 inhibitors, gene therapy, and bisphosphonates. The RCTs, systematic reviews, cohort, and case-control studies included in the review satisfied the *Critical Appraisal Skills Program (CASP)* [14].

2.1. Anti-Catabolic (Agents Preventing Cartilage Degeneration)

2.1.1. Low-Molecular Weight Human Serum Albumin Fraction (LMWF-5A)

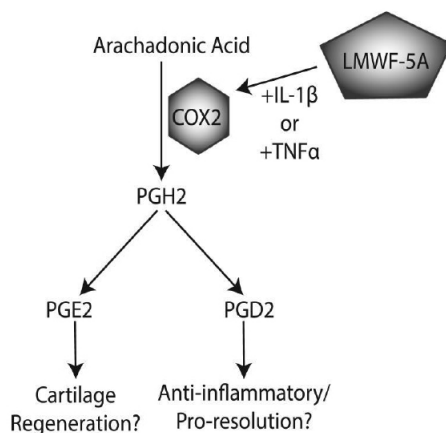
Cyclooxygenase-2 (COX2) has an established pro-inflammatory role; however, recent evidence suggests that COX2 is critical for the resolution after the initial activation phase of the immune response [15]. In culture media, fibroblast-like synoviocytes from OA-knee synovial membrane treated with LMWF-5A were found to release increased anti-inflammatory prostaglandin COX-2 mRNA/protein, prostaglandins (E2, D2), and promote resolution of inflammation and regeneration of damaged cartilage (Fig. 1) [15].

IA - LMWF-5A injections also have immune-modulating potential and demonstrated to be safe compared to vehicle control (saline) at 12-week follow-up [15, 16]; IA serum albumin injection led to reduced pain and improved physical function in moderate to severe OA-knee as measured by Western Ontario and McMaster Universities Osteoarthritis (WOMAC) index [16]. Schwappach *et al.* revealed that 2-weekly, 3-IA injections of 4-ml LMWF-5A, could be safe and effective in relieving OA-knee pain at 20-week follow-up [17]. In another clinical trial with 168 OA-knee cases, 71% of them received IA-LMWF-5A treatment, which led to significant improvement with the LMWF-5A arm compared with historical saline controls (65% vs. 43%, $p < 0.001$) [18]. IA-LMWF-5A could also reduce the incidence of total knee replacement (TKA) in severe OA [19]. IA - LMWF-5A is usually safe; however, mild-moderate adverse effects (AEs) common to any IA procedure could also happen. In a study, 34% of LMWF-5A intervention developed mild to moderate arthralgia. No severe AEs were recorded [18]. However, to assess the overall risk-benefit ratio of IA-LMWF in OA knee, long-term follow-up is required.

Table 1. Emerging treatment options for knee osteoarthritis.

Class of Interventions	Mechanism of Action	Mode of Application
Low-molecular weight human serum albumin fraction (LMWF-5A) [15-19].	Anti-inflammatory and immune modulating potential in knee osteoarthritis (OA)	Intra-articular (IA) injection
Disease modifying anti-rheumatic drugs (DMARDs), metformin and statins [20-35]	Methotrexate (MTX), hydroxychloroquine (HCQ), and statin cause a release in glycosaminoglycans, tumor necrosis factor- α (TNF- α), matrix metalloproteinase-13 (MMP-13), and O ₂ in treatment of OA, role of statin in OA knee progression or halt is yet to appear clear	MTX could be used both through route IA and orally; HCQ is given orally
Nerve growth factors inhibitors (NGFs) [36-45]	Monoclonal antibody antagonizing NGFs	tanezumab, fasinumab, fulranumab could be given IA
Bone morphogenetic protein (BMP) - 2, 7 [46-52]	BMP-7 has a strong anabolic effect on cartilage by stimulating synthesis of cartilage matrix components and increasing proteoglycan and collagen synthesis; BMP2 is an important protein component involved in the maintenance of the structure and function of articular cartilage	IA injection
Platelet rich plasma (PRP) [53-72]	PRP, a volume of plasma with higher platelet concentrate than that average in peripheral blood and causes tissue healing including degenerated joint cartilage releasing various growth factors	IA injection periodically
Mesenchymal stem cell (MSC) therapy [73-87]	Embryonic, fetal and adult stem cell, having differential potential to cartilage specific chondrocytes	IA injection of MSC, iPSC, ESC
Exosomes [84, 88-90]	Exosomes are cells secreted vesicles mediating cross talk between them with related biological processes such as chondrocyte homeostasis, cartilage healing, etc.	Transfection of purified exosomes from modified MSCs could be injected IA for cartilage healing in OA knee
Fibroblast growth factors (FGFs) [91-98]	FGF has shown the potential effects on the repair and regeneration of tissue. It is capable of promoting fibroblast proliferation and there are 22 members. They exert functions through FGF receptors activating Ras-MAPK pathway. With their potential biological functions, FGFs have been utilized for the regeneration of damaged tissues, including, articular cartilage.	IA injection
Interleukin (IL-1) blockers [99-108].	Blocking of interleukin-1	IA injection (Anakinra), SC (Cinacimab)
Gene therapy [109-111]	Genetically engineered chondrocytes overexpress TGF- β 1 and promotes biological process required for healing of damaged cartilage	<i>in vivo</i> and <i>in vitro</i> approach of IA gene delivery
Bisphosphonate [112-116]	Altered bone turnover and preserve adjacent articular cartilage	Oral (daily, weekly, monthly, quarterly), and yearly injection

LMWF-5A, Low-molecular weight human serum albumin fraction; IA, intra-articular; DMARDs, disease modifying anti-rheumatic drugs; MTX, methotrexate, MAPK, mitogen-activated protein kinase; HCQ, hydroxychloroquine; TNF- α , tumor necrosis factor- α ; MMP-13, matrix metalloproteinase-13; NGFs, nerve growth factors inhibitors; BMP, bone morphogenetic protein; FGFs, fibroblast growth factors; PRP, platelet rich plasma; MSC, mesenchymal stem cell; iPSC, induced pluripotent stem cell, ESC, embryonic stem cell; SC, subcutaneous; IL-1, interleukin-1; TGF, transforming growth factor.



PGE2, prostaglandin E2, PGH2, prostaglandin H2, PGD2, prostaglandin D2, IL, interleukin, TNF, tumor necrotic factor, COX2, cyclooxygenase 2, LMWF-5A, low molecular weight human serum albumin fraction.

Fig. (1). LMWF-5A promotes regenerating damaged cartilage in OA [15].

2.1.2. Disease Modifications with DMARDs, Statins and Metformin

Unlike in inflammatory rheumatic diseases, DMARDs appeared ineffective in OA-knee [20]. However, three recent studies documented methotrexate (MTX)-mediated improvement of pain, WOMAC stiffness, physical function, and quality of life (QoL) scores after 3 and 6 months in OA-knee [21-23]. The analgesic effect of MTX was significant but of borderline clinical effect size [23]. DK226, a hyaluronic acid and methotrexate conjugate, exerts anti-arthritis effects in an animal model and could be a hope for inflammatory OA [24]. Hydroxychloroquine (HCQ) also appeared promising in the treatment of OA-knee [25]. But, a recent meta-analysis of RCT revealed that DMARDs (biologics and conventional) had neither statistical nor clinical significance in managing OA [20]. Further studies may shed light on the efficacy of DMARDs in OA-knees [20, 24]. Atorvastatin - HCQ combination trial in OA-knee is yet to be finished [26].

Metformin [27, 28] and statins [29, 30] appeared chondroprotective in preclinical and clinical OA-knee research. In an *in vivo* animal OA-knee model study, simvastatin caused Wnt (*Wnt is a portmanteau of int and Wg oncogenes and stands for "Wingless-related integration site") / β -catenin signaling pathway inhibition and prevented intra-nuclear translocation of free cytosolic β -catenin that resulted in Wnt-dependent transcriptional activity inhibition for chondrocyte dedifferentiation and cartilage degeneration as confirmed by increased type II collagen expression and induced sulfated proteoglycan synthesis under Western blot technique [29]. Preclinical study with human OA articular cartilage-derived chondrocytes treated *in vitro* statin-rich (simvastatin) media reversed the pro-inflammatory cytokine (IL-1 β) mediated effects on damaged cartilage, and the effects were statin dose-dependent reduced expression of mRNA of MMP-3, 13; increased expression of mRNA of aggrecan and collagen2a1 proteins [30]. In a population-based Dutch cohort study, OA-knees aged over 55 years were followed up. Overall radiological progression was reduced by more than 50% among statins users than non-statin users [31]. However, a West-European study documented worsening of tibiofemoral radiological joint space over three years among statin users [32]. Besides, a Swedish human study could not confirm the reduced incidence of OA-knee consultation or surgery among statin users [33].*

In a longstanding cohort with US obese OA-knee patients, metformin appeared to preserve cartilage volume and reduce TKA [28]. A COX-2 inhibitor-metformin combination was also documented to reduce TKA incidence among Taiwanese [27]. Metformin stimulated adenosine monophosphate-activated protein kinase (AMPK), and adipose-tissue-derived MSC (ADMSC) showed a chondroprotective effect in animal OA-knee [34, 35]. Metformin caused up-regulation of phosphorylated and total AMPK expression in articular cartilage tissue with inhibition of synovial hyperplasia and osteophyte formation [34]. Metformin also halted OA progression in partial medial meniscectomy non-human pri-

mates [34]. As preclinical studies are promising and the findings of clinical studies are conflicting, an RCT to study the effect of oral statins in patients with knee OA still seems feasible [30, 31, 33]. As in animals, the impact of IA statins appears to be promising; a pilot phase-II clinical trial with a limited number of OA knee cases appears to be indicated. DMARD are found ineffective in OA knee [20]; the long-term follow-up outcomes of clinical research regarding the efficacy of metformin and statin could explore the safety profile with risk-benefit aspects of these agents for clinical use.

2.1.3. Nerve Growth Factors (NGFs) Antagonists

Nowadays, NGFs are considered promising as pain mediators and antagonists targeting NGFs mediated pain relief. Available anti-NGFs are tanezumab, fasinumab, and fulranumab, of which tanezumab is most widely studied in OA-knee [36-38]. Pain reduction had been documented in pre-clinical and clinical trials with various anti-NGFs in degenerative arthritis [38, 39]. A recent animal study showed further promise in OA-knee treatment with anti-NGF antibodies. Intra-peritoneal injection of anti-NGF antibody improved gait pattern in mice-induced OA-knee [40]. Similarly, active immunization (therapeutic and prophylactic) targeting NGF documented reversibly attenuated chronic pain behavior in murine OA-knee models [40].

However, osteonecrosis and rapidly progressive OA (RPOA) in target and non-target joints made the scientific societies alarmed about the safety profiles of this drug group, leading to a temporarily FDA imposed a ban on June 22, 2010, on all clinical trials with all anti-NGFs, though lifted later on March 12, 2012 [38, 41]. FDA-approved phase-III clinical trials with subcutaneous tanezumab in human OA-knees revealed a dose-dependent response: tanezumab 5 mg statistically significantly improved pain, physical function, and patient's global assessment of OA, whereas tanezumab 2.5 mg only improved WOMAC pain and physical function [42]. In an RCT, fasinumab significantly reduced WOMAC pain in moderate-severe OA-knee; further studies may unveil its minimum effective dose [43].

Trials concerning anti-NGFs safety were performed [42, 44]. Chen *et al.* reported that a reduced tanezumab dose (≤ 2.5 mg) not only caused OA pain relief but also caused fewer AEs [44]. Tanezumab could lead to primary osteonecrosis and subchondral insufficiency fracture. Some may require joint replacement therapy during and after the anti-NGF treatment [42]. Paraesthesia and hypoaesthesia with or without discontinuation could happen with the tanezumab 2.5-5 mg dose. Peripheral neuropathy, including carpal tunnel syndrome, could be a reported complication of anti-NGF therapy. Besides, infusion-related sympathetic nervous system function-related AEs such as bradycardia, orthostatic hypotension, and syncope could also happen with dose-dependent tanezumab therapy [42]. Patients also develop arthralgia, peripheral edema, and extremity pain [45].

Early clinical trials documented anti-NGFs mediated RPOA that addressed changes to the future related trial designs to minimize the RPOA risk and assess aspects of joint

safety. Careful monitoring of anti-NGFs associated AEs in clinical trials is needed to clarify this emerging OA medication class's overall risk-benefit ratio, particularly with long-term use [45].

2.2. Anabolic (Agents for Cartilage Regeneration)

2.2.1. Bone Morphogenetic Protein (BMP) Induced Cartilage Formation

BMP-7 profoundly affects chondrocyte metabolism, including synthesis, organization, and retention of matrix molecules but not chondrocyte proliferation [46]. Increased serum and SF - BMP-2 levels were found in patients with advanced OA-knee (grade-4 KL score) than in patients with early OA knees and healthy controls [47]. With increased age and progressive articular cartilage degeneration, the expression level of endogenous BMP - 2, 7 decreases gradually. A decrease in synovial fluid (SF) BMP - 2, 7 might play an essential role in the progression of cartilage degeneration, and patients could benefit from IA - BMP-2,7 injections [46, 48]. Exogenous BMP-2 stimulates recently isolated human articular cartilage chondrocytes and synthesis Col2A [46]. In a rabbit OA-knee model, IA or continuous pump of BMP-7 can stop articular cartilage degeneration without any significant AE [49]. In an RCT, in patients with symptomatic OA-knees, Hunter *et al.* found positive clinical outcomes following IA injection of BMP-7, without dose-limiting side effects [48].

As BMP is relatively short-lived, a single injection might not be effective in achieving the therapeutic outcome, and multiple injections or a sustained delivery system could be required. In an *in vivo* pre-clinical study, sustained delivery of BMP2 *via* a BMP2-coacervate effectively induced differentiation of muscle-derived stem cells to a chondrocyte lineage for cartilage regeneration [50]. The mRNA expression of aggrecan (AGC) and Col2A signifying chondrogenic differentiation was highest where sustained BMP2 is delivered *via* BMP-coacervate [50]. Both BMP - 2 and 7 appeared promising disease-modifying agents for OA patients and are currently under phase-II trial [51, 52]. Human MSC, including ADMSCs, treated with BMP-4, 6, and 9 modulate *in vitro* cartilage development [46]. Recently, in a case-control study, a significant association of rs1470527 and rs9382564 polymorphism of BMP - 5 gene with human OA-Knee has been demonstrated; this also may be a potential therapeutic target for OA [52].

IA-BMP injection is safe; in a study, David and colleagues demonstrated no significant difference between the BMP and placebo groups in terms of AEs documented following BMP-7 injection [48]. They were of mild category and limited to mild joint pain, swelling, injection site bruising, headache, nasopharyngitis, *etc.* [48]. There were no life-threatening AEs and death. No radiographic abnormalities consistent with ectopic bone formation were reported in follow-up. No patients developed anti-BMP-7 binding antibodies during the study [48]. However, further research to test the safety profile of IA-BMP is required.

2.2.2. Orthobiologic (Platelet-Rich Plasma, PRP)

PRP enriched with growth factors like platelet-derived growth factor, insulin-like growth factor, vascular endothelial growth factor, and transforming growth factor (TGF) beta-1 is shown to be effective in healing injured cartilage [53]. It has a proliferative effect on autologous chondrocytes [53]. PRP supplemented chondrocytes cause glycosaminoglycan formation in tissue-engineered cartilage with greater compressive mechanical properties [54]. In an *in vitro* study with human OA-knee chondrocytes, PRP releasate (PRPr) was shown to have diminished IL-1 beta mediated inhibition of Col2A1 and AGC gene expression through *nuclear factor kappa B* (NF κ B) pathway activation [55].

IA-PRP improves pain, overall QoL, synovitis, patellofemoral cartilage volume, and Whole-Organ MRI Score in OA-knee [56, 57]. It also improves joint stiffness, WOMAC overall scores, synovitis score, and ADL at 6- and 12-month in MRI defined EOA knees, compared with baseline in 73.3% and 83.3% cases, respectively at 1-year follow-up [57, 58], though without any qualitative MRI change in medial and lateral femoral compartments [57, 58]. In a recent trial with human OA-knee, both PRP and PRP with growth factors were more effective than ozone therapy [59]. Another study comparing the efficacy of IA-PRP and IA-HA in 192 OA-knee revealed that both treatments were equally effective, with sustained improvement up to 24 months; however, the re-intervention rate at 24 months was lower in PRP recipients [60]. A recent meta-analysis of RCT compared the efficacy of IA PRP-HA and IA-HA in symptomatic knee OA; the study depicted the remarkable improvement of WOMAC pain, stiffness, and function scores IA PRP-HA group as assessed 3-monthly for 12 months [61].

Sports personnel with OA-knee treated with PRP experienced pain relief and improved physical function; however, only 50% of them could successfully return to sports [62]. In a study, Su *et al.* demonstrated the superiority of IA plus intra-osseous PRP over IA-PRP and IA-HA in OA-knee with sustained lower VAS-pain scores, improved WOMAC, and QoL scores within the next 18 months [63]. Another RCT studied patients with mild-moderate OA-knee receiving IA-PRP had comparable outcomes with clinically significant functional improvement for at least 1-year [64]. IA injections of HA, PRP, and corticosteroid combination is found an effective and safe at least for short-term in relieving WOMAC pain and physical function and QoL scores, especially in younger patients and mild-moderate OA cases [65]; positive outcomes were sustained for at least 25 months, particularly in EOA-knee patients [65]. PRP also appeared effective in combination with biocompatible carriers/scaffolds like gelatin hydrogel, chitosan, polylactic-co-glycolic acid mesh, and β -tricalcium phosphate scaffolds in OA-knee [66]. Photo-activated PRP (10-minute exposure to monochromatic light) improved pain, stiffness, and function in mild-moderate OA-knees [67]. PRP supplemented with home-based strengthening and stretching exercises addressing calf and hamstring muscles provided better pain relief, improved joint ROM, and WOMAC scores than only PRP or

only therapeutic exercise intervention for OA-knees [68].

PRP therapy is a simple, minimally invasive, and cost-effective intervention for OA-knee. We are yet to have precise data regarding PRP's accurate composition, intrinsic and extrinsic factors modifying its efficacy, optimal dosage, duration between injections, injection frequency, when to inject after preparing PRP, therapeutic effectiveness, cost-effectiveness, and post-injection rehabilitation [59, 69, 70]. PRP could be more effective in early OA-knee [64, 65]; nevertheless, recent works documented its cartilage regenerating potential regardless of cartilage damage level [56]. In their recent annual congresses, NICE and the European Congress of Rheumatology (EULAR) recommended PRP as the second-line treatment option in OA-knee [70, 71].

IA-PRP is usually safe [65]. However, published research reported the following complications after PRP injection: dizziness, headaches, nausea, gastritis, sweating, tachycardia, and all they said self-limiting. In addition, there could be post-injection pain, swelling, and limited daily activities and could resolve within 3-4 days [53, 65, 72]. No study documented the long-term AEs of PRP; hence, a time-to-event prospective survey could be the answer.

PRP shows promise in the OA trials; however, some studies depicted PRP as not the answer to articular cartilage degeneration. RCTs favor PRP use over other IA treatments for the short and medium-term; however, most evidence was of the poor level of evidence. They were further biased regarding PRP preparation methods, platelet concentration, platelet activation before injecting, indications, injection frequency, precautions, and instructions to follow after injecting. At the moment, without further standardization of PRP protocol, the therapeutic aspects (risk and benefit) of PRP will remain an issue of open debate [53]. PRP's risk-benefit issue regarding its clinical applicability depends on these topics; we hope scientists' future endeavors will mitigate them.

2.2.3. Orthobiologic (Mesenchymal Stem Cell, MSC)

The American Society of Interventional Pain Physicians endorsed homologous bone marrow concentrate (BMC) in musculoskeletal disorders [73]. Early phase clinical trials with MSC injections unveiled beneficial effects on articular cartilage and subchondral bone [74]. Multi-potent MSC can be isolated from adipose tissue, blood, and bone marrow; their immune-modulatory, reparative, and anti-inflammatory properties were depicted in pre-clinical and clinical research [75, 76].

Autologous BMMSCs therapy in OA-knee appeared safe, improved pain and symptoms, and reduced synovial inflammation at 12-months [75]. Autologous ADMSCs (adipose-tissue derived MSC) also improved pain, function, and MRI - OA scores in symptomatic OA-knee at 12-month follow-up without serious AEs [76]. Full-thickness injured knee cartilage treated with HA and BMC-MSc provides good-excellent clinical outcomes at long-term follow-up irrespective of the extent of the injury, number of lesions, and joint compartments involved, specifically in younger cases

[77]. Similarly, in advanced OA-knee, a single IA injection of 1, 10, or 50 million BMMSCs revealed significant overall improvements of pain, QoL, WOMAC stiffness score, dose-dependent improvement of ROM, cartilage catabolic biomarkers, and MRI synovitis scores in a phase I/IIa trial [73, 75].

Irrespective of ADMSCs cell dosage, improvements of sustained pain score, functional (WOMAC), and structural (MRI-based) improvements lasted a maximum of 24 months [76]. There were no treatment-related AEs. A statistically significant improvement in higher dose groups was found, and clinical outcomes tended to deteriorate after one year in the low- and medium-dose groups [78]. Besides, OA-knee receiving subchondral BMC treatment could postpone TKA for a period of a mean of ten years [79].

In patients with deformed OA-knees treated with distal femoral osteotomy and human umbilical cord blood-derived (hUCB)-MSCs, improved pain and WOMAC scores were seen, and modified two-dimensional MRI showed cartilage repair [80]. Repeated hUCB-MSc treatment is found safe with superior efficacy over IA-HA in symptomatic OA-knee at 1-year follow-up [81]. In OA-knee rat models, a single IA injection of hUCB-MSCs temporarily decelerates cartilage degeneration [82]. In another animal study, transfected hUCB-MSCs with miR-140-5p mimics and miR-140-5p lentivirus over-expressing miR-140-5p (microRNAs) in rat OA-knee models signified its cartilage healing potential [83]. Induced MSC exosomes also showed a more significant cartilage regeneration potential in collagenase-induced mouse OA-knee [84].

In a rat OA-knee model study, extracorporeal shock-wave therapy (ESWT) and ultrasonogram guided injection of autologous ADMSC showed a greater chondroprotective effect over ESWT and human umbilical cord Wharton's jelly-derived mesenchymal stem cells [85]. MSCs or stromal vascular fraction (SVF) seem to produce promising good-excellent clinical and pre-clinical results for knee-OA treatment; however, we still lack RCT considering the large sample size [75].

MSC therapy may have few AEs. Most of them are limited to mild joint pain and swelling that improve with analgesic and NSAIDs like ibuprofen; sometimes, overnight observation relieves the pain [86]. In a patient, incidental unstable angina was documented three months after injection. No clinical evidence suggests that treatment with MSCs of any type increased the cancer risk [86].

MSC is proved safe in human OA [75-79]. MSCs will be widely used in clinical OA with the gradual improvement of related technologies and processes. It is yet to appear clear to know which molecular pathways and chemicals of MSC contribute to cartilage regeneration. Furthermore, injection quantity, source, and preservation technique, and combining MSC with sodium hyaluronate, steroid, PRP are worth exploring its risk and benefits aspects [87].

2.2.4. Exosomes

Exosomes are secreted vesicles; they mediate cell cross-talk and related biological processes [88]. In OA, exosomes releasing from chondrocytes accelerate IL-1 β -mediated synovial inflammation, reducing anabolic and increasing catabolic chondrocyte gene expression [88, 89]. However, human-induced pluripotent stem cell-derived MSC (hiP-SC-MSCs) released exosome (iMSC-Exos) and synovial membrane MSC exosome (SMMSC-Exos) could attenuate OA-knee progression; chondrocyte migration and proliferation; the inhibition of progression is greater with autologous iMSC-Exos over SMMSC-Exos [84]. PRP, bone marrow, adipose tissue, and embryonic tissue-derived MSC-Exos also maintain chondrocyte homeostasis and ameliorate the OA severity [84, 88, 90]. Both *in vitro* and *in vivo* studies of transfection of exosomes from modified MSCs loaded with miRNA (miR-92a-3p, miR-140-5p, miR-320c), long non-coding RNA (lncRNA-KLF3-AS1) appear to be promising for OA-knee treatment [89]. Genetically engineered primary chondrocytes can repair injured cartilage in OA-knee [89]. As we are unsure of several aspects of exosomes, further studies addressing its mechanism of action, isolation techniques, diagnostic, and therapeutic potentials in OA are required. Advanced technology may clarify these questions regarding exosome-based therapy in the treatment of OA-knees in the future [88].

Limited preclinical evidence explored the aspects of exosomes to be helpful in OA. We don't have direct proof of transferring endogenous exosomes from cell to cell in the joint *in vivo*, limited further studies. Further clarification on exosomes sources, how they work on their targets, or how they penetrate deeper parts of degenerated cartilage are required. We are yet to learn in-depth the chondroprotective miRNA profile of exosomes. We hope the coming days' research will address these aspects of exosomes therapy to help us understand its risk-benefit in clinical OA knee [88].

2.3. Anabolic and Anti-Catabolic (Agents Cause Cartilage Regeneration and Stop Cartilage Degeneration)

2.3.1. Fibroblast Growth Factor (FGF) - Mediated Cartilage Regeneration (Anabolic and Anti-Catabolic)

Basic fibroblast growth factor (bFGF) or FGF-2 is a polypeptide that plays an essential role in tissue regeneration [91, 92]. Nummenmaa *et al.* demonstrated that FGF-2 induced catabolic and anti-anabolic effects in OA-knee patients by up-regulating the production of matrix-degrading MMP-1, 13 enzymes, and down-regulating the *de novo* synthesis of aggrecan and collagen II in articular cartilage. An FGF-2 receptor antagonist appeared to be promising in OA-knee treatment [91]. Li *et al.* documented increased SF - FGF-1/FGF in patients with advanced OA than controls [92]. Increased plasma bFGF/FGF-23 levels are associated with both clinical and radiological severity of human primary OA and may be potential biomarkers for diagnosing and monitoring knee OA [91-93]. Higher plasma FGF-23 levels in patients with OA-knee were found in joint effusion

cases and bilateral OA. Increased serum- and SF FGF-21 concentrations were also associated with radiographic progression in knee OA, making it a potential biomarker to predict cartilage damage and a therapeutic target in OA patients [94].

S100B, a 21 kilodaltons (kDa) EF hand-type cytosolic calcium-binding protein, causes FGFR1 signaling-mediated inflammatory response. In diseased human cartilage, S100B is up-regulated, and extra-cellular S100B promotes cartilage degradation. A recent study in rabbit OA-knee models revealed higher S100B expression associated with increased SF - TNF- α and IL-1 β levels [95]. Besides, S100B-mediated fibroblast stimulation in synovial tissue resulted in FGFR1 signaling-mediated inflammatory response (increased expression of FGF1 mRNA, FGFR1 mRNA, and respective proteins and decreased type-II collagen), making it a potential therapeutic target as well for OA [95].

Sprifermin (recombinant human fibroblast growth factor 18; rhFGF18) promotes chondrogenesis and cartilage matrix production activating fibroblast growth factor receptor 3 (FGFR-3) in cartilage as tested *in vivo* and *in vitro* studies [96, 97]. Among patients with symptomatic, radiographic OA-knee and KL grade - 2 or 3, IA administration of 100 μ g of FGF-18 (sprifermin) every 6 or 12 months *versus* placebo resulted in a significantly increased total femorotibial joint cartilage thickness after two years, but no clear clinical effect; a significant difference was also found with 30 μ g sprifermin every 6 or 12 months over placebo; however, the durability of the response was uncertain [96]. Dose-dependent response in terms of medial tibiofemoral thickness has not been achieved with any sprifermin dose [96].

Sprifermin was not associated with any significant local or systemic safety concerns [96, 97]. No deaths were reported. There was no statistically significant dose-response relationship between increasing occurrences of acute inflammatory reactions and increasing doses. Treatment-emergent AEs mainly mild, including arthralgia and joint swelling, injection site pain, nasopharyngitis, hypertension, and headache. Acute inflammatory responses could also be reported. AEs led to treatment discontinuation, or trial withdrawal is infrequent. Severe AEs considered unrelated to the treatment or unlikely to be related to the study, for example, bacterial arthritis [96, 97].

In a recent meta-analysis, IA sprifermin was also reported safe in KOA without any specific AEs. Injection sprifermin may lead to cartilage thickness, volume, and surface morphology improvement; however, it proved no positive impact on symptom alleviation. More evidence is still required for its efficacy and safety to be regarded as a disease-modifying OA agent [98].

2.4. Inhibition of Interleukin-1 (IL-1)

Several human studies report that members of the IL-1 family are found in both SF and synovial membranes of OA knees. Blocking various members of the IL-1 family in murine models showed cartilage protective effects [99]. In

early OA, infiltrating myeloid cells are a major source of IL-1 locally; as the disease progresses, there are fewer infiltrating myeloid cells, and the role for IL-1 may be gone. IL-1 β , more than any other cytokines, has been linked to the pathogenesis of destructive OA. In OA, synovial cells induce COX2 enzyme and PGE2 synthesis through IL-1; hence, the widespread use of oral COX-2 inhibitors could well target pain and cartilage degradation [100]. A reduction in IL-1 β in OA is chondroprotective, which is echoed in RA patients treated with anakinra [100, 101]. In a clinical study, no uniform association was found between IL-1 β / TNF- α production and radiographic OA in either sex [102]. However, a possible association could exist between the highest levels of IL-1 β production and knee osteophytes (OR=2.0, 1.2-3.5) and joint space narrowing (OR=1.7, 1.1-2.8) in women [102]. Parenteral administration of IL1R1 (AMG108, a fully human immunoglobulin subclass G2 monoclonal antibody binding the human IL-1 receptor type 1, IL-1a and IL-1b), ABT-981, and canakinumab [103-105] were all promising in OA. Based on a recent clinical trial, subcutaneous canakinumab (50-300 mg) was effective in reducing the incidence of total TKA, preferably in primary OA; however, further study was suggested [106]. Other oral small molecules such as selective NLRP3 inflammasome inhibitors are considered promising in this respect [107].

The safety profile of AMG 108 and placebo injection are comparable in human OA knee trials [103]. Injection site pain was the most common AE. SAEs' profile of patients receiving IV and SC anti-IL1 (100 and 300 mg) included hemorrhagic diarrhea, unstable angina, lobar pneumonia, respiratory failure, multi-organ failure, sepsis, neutropenia, and leukopenia in the other, pancreatitis, and supraventricular tachycardia [103]. Early studies using therapeutic approaches in large animal models offered benefits, but IL-1 α/β , IL-1-converting enzyme, and IL-1 receptor knocked out murine failed to stop developing OA [108]. Recent RCTs regarding the usefulness of IL-1 inhibitors in human knee OA concluded a lack of efficacy [108]. Hope future study could explore risk-benefit aspects of IL inhibitors in OA knee.

2.5. Gene Therapy (Genetically Engineered Chondrocytes)

The arthritis gene therapy concept was first published in 1992 [109]. In 2015, a phase-II trial unveiled genetically engineered chondrocytes virally transduced with TGF- β 1 applicable in OA-knee [109]. Later in 2017, South Korea first approved gene therapy for OA treatment [110]. In a phase-III trial, IA TissueGene-C (TG-C) was shown to improve VAS pain and WOMAC (pain, stiffness, and physical function) scores in OA-knee [110]. In another phase-III trial, INVOS-SA (cell and gene therapy, allogeneic non-transformed and retrovirally transduced chondrocytes to over-express TGF- β 1) caused improved pain and function [111]. Both INVOS-SA and TG-C have OA disease-modifying potentials [110, 111]. The most frequent AEs in the TG-C group were peripheral edema, arthralgia, joint swelling, and injection site pain. The SAEs were not observed [110]. Gene therapy is at its infancy regarding OA knee treatment; we are yet to have

more data regarding the outcomes of gene therapy in OA knee.

2.6. Drugs Affect Bone Turnover and Prevent Cartilage Degeneration

Increased evidence suggests that high bone turnover plays an essential role in the initiation and progression of cartilage degeneration in OA, leading to an increased interest in drugs affecting bone metabolism, such as bisphosphonate. In a recent prospective open-label trial in Italy, eighteen consecutive patients with painful knee prosthesis and OA received parenteral (IV or IM) clodronate (CLO) (induction dose was 2.0-2.1g, followed by a weekly dose of 200 mg IM for six months) and knee rehabilitation (knee physiotherapy and walking). Following the intervention, VAS pain (8.1 ± 1.8 to 5.6 ± 2.6 , $p<0.05$) and Tegner Lysholm Score (TLS, a patient-reported outcome tool following knee ligament surgery) (40.4 ± 20.3 to 62.7 ± 24.1 , $p<0.05$) improved significantly at six months. BMI was also seen positively correlated with VAS ($r=0.73$, $p=0.004$) and lower TLS at one month ($r=-0.62$, $P=0.006$). Administration of a high dose (induction dose) of CLO every three months appeared to be the most effective regimen compared to a weekly regimen [112]. In another recent cohort with radiographic OA knee, bisphosphonates were found to stop radiographic progression in non-overweight OA cases. Propensity-matched results indicated that bisphosphonate users (69% alendronate) with KL grade <2 were protected against progression than bisphosphonate users with KL grade ≥ 2 . This effect is more substantial among those with lower BMI (<25 kg/m 2); however, the duration of bisphosphonate exposure did not affect OA knee progression [113]. An earlier meta-analysis of 15 RCTs by Xing *et al.* also indicated that bisphosphonates therapy could relieve pain and stiffness and accelerate functional recovery for OA but can't stop OA progression [114].

However, in a meta-analysis of seven RCTs, including 3013 patients Vaysabrot and colleagues demonstrated no promising bisphosphonate's effects on OA knee - it neither provided symptomatic pain relief nor improved physical function or radiographic progression; only a small RCT suggested high subchondral bone turnover was reduced with Bisphosphonates (alendronate 70 mg/week) at six months, though the overall risk of study bias was high [115]. Bisphosphonates displayed good tolerability, with no statistically significant differences in AE outcomes over placebo [115]. Effects of IV zoledronic acid (5 mg in a 100-mL saline solution) on knee cartilage volume loss in symptomatic KOA with MRI-detected subchondral bone marrow lesions further studied in multiple Australian centers over two years period; however, the outcomes were not promising [116]. The study demonstrated no significant difference between the zoledronic acid and placebo groups in terms of cartilage volume ($p=.50$), VAS knee pain ($p=.17$), WOMAC physical function scores ($p=.21$), and bone marrow lesion sizes ($p=.60$). AEs were more common with zoledronic acid than placebo (96% versus 83%, respectively) and consisted mainly of acute reactions within three days of infusion administration; 87% versus 56%) [115]. Study outcomes regarding the effi-

cacy of bisphosphonate intervention in OA knee are inconsistent and inconclusive; further study is required to document its usefulness in OA knee, safety profile, and risk-benefit ratio.

CONCLUSION

Osteoarthritis may lead to chronic disability if left untreated for a long-time. Even the most prudent healthcare facility cannot provide a complete cure for the disorder following state-of-the-art approaches. Some of the reported emerging interventions are found helpful in joint degeneration, especially in early osteoarthritis. However, the outcomes of some other interventions are inconclusive, and they are based on low-quality evidence-based studies and warrant further research.

KEY MESSAGES

1. Intra-articular human serum albumin, nerve growth factors antagonists, bone morphogenetic proteins, fibroblast growth factors, orthobiologics, exosomes, interleukin-1 blockers, gene-based therapy, and bisphosphonate appear promising in OA knee treatment.

2. The role of conventional disease-modifying anti-rheumatic drugs (DMARDs), lipid-lowering agents (statin), and metformin in OA knee management is unclear.

3. Further research addressing OA knee treatment should be done.

DISCLOSURES

The authors have nothing to disclose regarding this study

CONSENT FOR PUBLICATION

Not applicable.

FUNDING

This research received no specific grant from any funding agency in the public, commercial, or not for-profit sectors.

CONFLICT OF INTEREST

The authors declare no conflict of interest, financial or otherwise.

ACKNOWLEDGEMENTS

Declared none.

REFERENCES

- [1] Berenbaum F. Osteoarthritis as an inflammatory disease (osteoarthritis is not osteoarthrosis!). *Osteoarthritis Cartilage* 2013; 21(1): 16-21. <http://dx.doi.org/10.1016/j.joca.2012.11.012> PMID: 23194896
- [2] Favero M, Ramonda R, Goldring MB, Goldring SR, Punzi L. Early knee osteoarthritis. *RMD Open* 2015; 1: e000062. <http://dx.doi.org/10.1136/rmdopen-2015-000062> PMID: 26557380
- [3] Zhang Y, Jordan JM. Epidemiology of osteoarthritis. *Clin Geriatr Med* 2010; 26(3): 355-69. <http://dx.doi.org/10.1016/j.cger.2010.03.001> PMID: 20699159
- [4] Chua JR, Jamal S, Riad M, *et al.* Disease burden in Osteoarthritis (OA) is similar to Rheumatoid Arthritis (RA) at initial rheumatology visit and significantly greater six months later. *Arthritis Rheumatol* 2019; 71(8): 1276-84. <http://dx.doi.org/10.1002/art.40869> PMID: 30891933
- [5] Luyten FP, Bierma-Zeinstra S, Dell'Accio F, *et al.* Toward classification criteria for early osteoarthritis of the knee. *Semin Arthritis Rheum* 2018; 47(4): 457-63. <http://dx.doi.org/10.1016/j.semarthrit.2017.08.006> PMID: 28917712
- [6] Klement MR, Sharkey PF. The significance of osteoarthritis-associated bone marrow lesions in the knee. *J Am Acad Orthop Surg* 2019; 27(20): 752-9. <http://dx.doi.org/10.5435/JAAOS-D-18-00267> PMID: 30964755
- [7] Sadatsuki R, Ishijima M, Kaneko H, *et al.* Bone marrow lesion is associated with disability for activities of daily living in patients with early stage knee osteoarthritis. *J Bone Miner Metab* 2019; 37(3): 529-36. <http://dx.doi.org/10.1007/s00774-018-0950-z> PMID: 30187274
- [8] Chu CR, Williams AA, Coyle CH, Bowers ME. Early diagnosis to enable early treatment of pre-osteoarthritis. *Arthritis Res Ther* 2012; 14(3): 212-22. <http://dx.doi.org/10.1186/ar3845> PMID: 22682469
- [9] King LK, Marshall DA, Faris P, *et al.* BEST-Knee Research Team. Use of recommended non-surgical knee osteoarthritis management in patients prior to total knee arthroplasty: A cross-sectional study. *J Rheumatol* 2020; 47(8): 1253-60. <http://dx.doi.org/10.3899/jrheum.190467> PMID: 31732554
- [10] Hochberg M, Altman RD, April KT, *et al.* American College of Rheumatology. American College of Rheumatology 2012 Recommendations for the use of non-pharmacological and pharmacological therapies in osteoarthritis of the hand, hip and knee. *Arthritis Care Res (Hoboken)* 2012; 64(4): 465-74. <http://dx.doi.org/10.1002/acr.21596> PMID: 22563589
- [11] Zhang W, Ouyang H, Dass CR, Xu J. Current research on pharmacologic and regenerative therapies for osteoarthritis. *Bone Res* 2016; 4: 15040. <http://dx.doi.org/10.1038/boneres.2015.40> PMID: 26962464
- [12] Dieppe P, Goldingay S, Greville-Harris M. The power and value of placebo and nocebo in painful osteoarthritis. *Osteoarthritis Cartilage* 2016; 24(11): 1850-7. <http://dx.doi.org/10.1016/j.joca.2016.06.007> PMID: 27338671
- [13] Zhang W, Robertson J, Jones AC, Dieppe PA, Doherty M. The placebo effect and its determinants in osteoarthritis: Meta-analysis of randomised controlled trials. *Ann Rheum Dis* 2008; 67(12): 1716-23. <http://dx.doi.org/10.1136/ard.2008.092015> PMID: 18541604
- [14] CASP checklists. Available from: <https://casp-uk.net/casp-tools-checklists/>
- [15] Frederick ED, Hausburg MA, Thomas GW, Rael LT, Brody E, Bar-Or D. The low molecular weight fraction of human serum albumin upregulates COX2, prostaglandin E2, and prostaglandin D2 under inflammatory conditions in osteoarthritic knee synovial fibroblasts. *Biochem Biophys Res* 2016; 8: 68-74. <http://dx.doi.org/10.1016/j.bbrep.2016.08.015> PMID: 28955943
- [16] Bar-Or D, Salottolo KM, Loose H, *et al.* A randomized clinical trial to evaluate two doses of an intra-articular injection of LMWF-5A in adults with pain due to osteoarthritis of the knee. *PLoS One* 2014; 9(2): e87910. <http://dx.doi.org/10.1371/journal.pone.0087910> PMID: 24498399
- [17] Schwappach J, Dryden SM, Salottolo KM. Preliminary trial of intra-articular LMWF-5A for osteoarthritis of the knee. *Orthopedics* 2017; 40(1): e49-53. <http://dx.doi.org/10.3928/01477447-20160926-02> PMID: 27684085
- [18] Salottolo K, Cole B, Bar-Or D. Intra-articular injection of the anti-inflammatory compound LMWF-5A in adults with severe osteoarthritis: A double-blind prospective randomized controlled multi-center safety and efficacy trial. *Patient Saf Surg* 2018; 12: 11.

- [19] Schwappach J, Schultz J, Salottolo K, Bar-Or D. Incidence of total knee replacement subsequent to intra-articular injection of the anti-inflammatory compound LMWF-5A *versus* saline: A long-term follow-up study to a randomized controlled trial. *Patient Saf Surg* 2018; 12: 14. <http://dx.doi.org/10.1186/s13037-018-0162-4> PMID: 29881459
- [20] Persson MSM, Sarmanova A, Doherty M, Zhang W. Conventional and biologic disease-modifying anti-rheumatic drugs for osteoarthritis: A meta-analysis of randomized controlled trials. *Rheumatology (Oxford)* 2018; 57(10): 1830-7. <http://dx.doi.org/10.1093/rheumatology/key131> PMID: 29917100
- [21] Wenham CY, Grainger AJ, Hensor EM, Caperon AR, Ash ZR, Conaghan PG. Methotrexate for pain relief in knee osteoarthritis: An open-label study. *Rheumatology (Oxford)* 2013; 52(5): 888-92. <http://dx.doi.org/10.1093/rheumatology/kes386> PMID: 23300331
- [22] Enteshari-Moghaddam A, Isazadehfahar K, Habibzadeh A, Hemmati M. Efficacy of methotrexate on pain severity reduction and improvement of quality of life in patients with moderate to severe knee osteoarthritis. *Anesth Pain Med* 2019; 9(3): e89990. <http://dx.doi.org/10.5812/aapm.89990> PMID: 31497519
- [23] Kingsbury SR, Tharmanathan P, Keding A, *et al.* Significant pain reduction with oral methotrexate in knee osteoarthritis; results from a randomised controlled phase III trial of treatment effectiveness. *Arthritis Rheumatol* 2019; 27(S1): S84-5.
- [24] Tamura T, Higuchi Y, Kitamura H, *et al.* Novel hyaluronic acid-methotrexate conjugate suppresses joint inflammation in the rat knee: efficacy and safety evaluation in two rat arthritis models. *Arthritis Res Ther* 2016; 18: 79. <http://dx.doi.org/10.1186/s13075-016-0971-8> PMID: 27039182
- [25] Jokar M, Mirfeizi Z, Keyvanpajouh K. The effect of hydroxychloroquine on symptoms of knee osteoarthritis: A double-blind randomized controlled clinical trial. *Iran J Med Sci* 2013; 38(3): 221-6. PMID: 24174692
- [26] ClinicalTrials.gov Identifier: Genovese, M. Hydroxychloroquine/Atorvastatin in the Treatment of Osteoarthritis (OA) of the Knee. National Library of Medicine (US) NCT01645176, 2017.
- [27] Lu CH, Chung CH, Lee CH, *et al.* Combination COX-2 inhibitor and metformin attenuate rate of joint replacement in osteoarthritis with diabetes: A nationwide, retrospective, matched-cohort study in Taiwan. *PLoS One* 2018; 13(1): e0191242. <http://dx.doi.org/10.1371/journal.pone.0191242> PMID: 29385156
- [28] Wang Y, Hussain SM, Wluka AE, *et al.* Association between metformin use and disease progression in obese people with knee osteoarthritis: Data from the osteoarthritis initiative—a prospective cohort study. *Arthritis Res Ther* 2019; 21(1): 127. <http://dx.doi.org/10.1186/s13075-019-1915-x> PMID: 31126352
- [29] Yu SM, Han Y, Kim SJ. Simvastatin induces differentiation in rabbit articular chondrocytes *via* Wnt/ β -catenin pathway. *Eur J Pharmacol* 2019; 863: 172672. Available from: <https://www.sciencedirect.com/science/article/abs/pii/S0014299919306247?via%3Dihub> <http://dx.doi.org/10.1016/j.ejphar.2019.172672> PMID: 31542485
- [30] Simopoulou T, Malizos KN, Poultsides L, Tsezou A. Protective effect of atorvastatin in cultured osteoarthritic chondrocytes. *J Orthop Res* 2010; 28(1): 110-5. PMID: 19623662
- [31] Clockaerts S, Van Osch GJ, Bastiaansen-Jenniskens YM, *et al.* Statin use is associated with reduced incidence and progression of knee osteoarthritis in the Rotterdam study. *Ann Rheum Dis* 2012; 71(5): 642-7. <http://dx.doi.org/10.1136/annrheumdis-2011-200092> PMID: 21989540
- [32] Eymard F, Parsons C, Edwards MH, *et al.* Statin use and knee osteoarthritis progression: Results from a post-hoc analysis of the SEKOA trial. *Joint Bone Spine* 2018; 85(5): 609-14. <http://dx.doi.org/10.1016/j.jbspin.2017.09.014> PMID: 29037516
- [33] Michaëlsson K, Lohmander LS, Turkiewicz A, Wolk A, Nilsson P, Englund M. Association between statin use and consultation or surgery for osteoarthritis of the hip or knee: A pooled analysis of four cohort studies. *Osteoarthritis Cartilage* 2017; 25(11): 1804-13. <http://dx.doi.org/10.1016/j.joca.2017.07.013> PMID: 28756279
- [34] Li J, Zhang B, Liu WX, *et al.* Metformin limits osteoarthritis development and progression through activation of AMPK signalling. *Ann Rheum Dis* 2020; 79(5): 635-45. <http://dx.doi.org/10.1136/annrheumdis-2019-216713> PMID: 32156705
- [35] Park MJ, Moon SJ, Baek JA, *et al.* Metformin augments anti-inflammatory and chondroprotective properties of mesenchymal stem cells in experimental osteoarthritis. *J Immunol* 2019; 203(1): 127-36. <http://dx.doi.org/10.4049/jimmunol.1800006> PMID: 31142603
- [36] Shang X, Wang Z, Tao H. Mechanism and therapeutic effectiveness of nerve growth factor in osteoarthritis pain. *Ther Clin Risk Manag* 2017; 13: 951-6. <http://dx.doi.org/10.2147/TCRM.S139814> PMID: 28814877
- [37] Lane NE, Schnitzer TJ, Birbara CA, *et al.* Tanezumab for the treatment of pain from osteoarthritis of the knee. *N Engl J Med* 2010; 363(16): 1521-31. <http://dx.doi.org/10.1056/NEJMoa0901510> PMID: 20942668
- [38] Brown MT, Murphy FT, Radin DM, Davignon I, Smith MD, West CR. Tanezumab reduces osteoarthritic hip pain: results of a randomized, double-blind, placebo-controlled phase III trial. *Arthritis Rheum* 2013; 65(7): 1795-803. <http://dx.doi.org/10.1002/art.37950> PMID: 23553790
- [39] Miyagi M, Ishikawa T, Kamoda H, *et al.* Efficacy of nerve growth factor antibody in a knee osteoarthritis pain model in mice. *BMC Musculoskelet Disord* 2017; 18(1): 428. <http://dx.doi.org/10.1186/s12891-017-1792-x> PMID: 29100502
- [40] von Loga IS, El-Turabi A, Jostins L, *et al.* Active immunisation targeting nerve growth factor attenuates chronic pain behaviour in murine osteoarthritis. *Ann Rheum Dis* 2019; 78(5): 672-5. <http://dx.doi.org/10.1136/annrheumdis-2018-214489> PMID: 30862648
- [41] Miller RE, Malfait AM, Block JA. Current status of nerve growth factor antibodies for the treatment of osteoarthritis pain. *Clin Exp Rheumatol* 2017; 107(5): 85-7.
- [42] Berenbaum F, Blanco FJ, Guermazi A, *et al.* Subcutaneous tanezumab for osteoarthritis of the hip or knee: efficacy and safety results from a 24-week randomised phase III study with a 24-week follow-up period. *Ann Rheum Dis* 2020; 79(6): 800-10. <http://dx.doi.org/10.1136/annrheumdis-2019-216296> PMID: 32234715
- [43] Dakin P, DiMartino SJ, Gao H, *et al.* The efficacy, tolerability, and joint safety of fasinumab in osteoarthritis pain: A phase IIb/III double-blind, placebo-controlled, randomized clinical trial. *Arthritis Rheumatol* 2019; 71(11): 1824-34. <http://dx.doi.org/10.1002/art.41012> PMID: 31207169
- [44] Chen J, Li J, Li R, *et al.* Efficacy and safety of tanezumab on osteoarthritis knee and hip pains: A meta-analysis of randomized controlled trials. *Pain Med* 2017; 18(2): 374-85. PMID: 28034979
- [45] Schmelz M, Mantyh P, Malfait AM, *et al.* Nerve growth factor antibody for the treatment of osteoarthritis pain and chronic low-back pain: mechanism of action in the context of efficacy and safety. *Pain* 2019; 160(10): 2210-20. <http://dx.doi.org/10.1097/j.pain.0000000000001625> PMID: 31145219
- [46] Deng ZH, Li YS, Gao X, Lei GH, Huard J. Bone morphogenetic proteins for articular cartilage regeneration. *Osteoarthritis Cartilage* 2018; 26(9): 1153-61. <http://dx.doi.org/10.1016/j.joca.2018.03.007> PMID: 29580979
- [47] Liu Y, Hou R, Yin R, Yin W. Correlation of bone morphogenetic protein-2 levels in serum and synovial fluid with disease severity of knee osteoarthritis. *Med Sci Monit* 2015; 21: 363-70. <http://dx.doi.org/10.12659/MSM.892160> PMID: 25644704
- [48] Hunter DJ, Pike MC, Jonas BL, Kissin E, Krop J, McAlindon T. Phase 1 safety and tolerability study of BMP-7 in symptomatic knee osteoarthritis. *BMC Musculoskelet Disord* 2010; 11: 232. <http://dx.doi.org/10.1186/1471-2474-11-232> PMID: 20932341
- [49] Badlani N, Inoue A, Healey R, Coutts R, Amiel D. The protective effect of OP-1 on articular cartilage in the development of osteoarthritis. *Osteoarthritis Cartilage* 2008; 16(5): 600-6. <http://dx.doi.org/10.1016/j.joca.2007.09.009> PMID: 17977753
- [50] Hicks JJ, Rocha JL, Li H, Huard J, Wang Y, Hogan MV. Sus-

- tained release of bone morphogenetic protein 2 *via* coacervate improves muscle derived stem cell mediated cartilage regeneration in MIA-induced osteoarthritis. *Orthop J Sports Med* 2016; 4: 7. <http://dx.doi.org/10.1177/2325967116S00152>
- [51] BMP2 bone morphogenetic protein 2 2018. Available from: <https://www.ncbi.nlm.nih.gov/gene/650> Accessed on 04/02/2018.
- [52] Sharma AC, Srivastava RN, Srivastava SR, Agrahari A, Singh A, Parmar D. Evaluation of the association between a single-nucleotide polymorphism of bone morphogenetic proteins 5 gene and risk of knee osteoarthritis. *J Postgrad Med* 2017; 63: 151-156. <http://dx.doi.org/10.1177/2040622319825567> PMID: 30815245
- [53] Gato-Calvo L, Magalhaes J, Ruiz-Romero C, Blanco FJ, Burguera EF. Platelet-rich plasma in osteoarthritis treatment: Review of current evidence. *Ther Adv Chronic Dis* 2019; 10: 2040622319825567. <http://dx.doi.org/10.1177/2040622319825567> PMID: 30815245
- [54] Petretera M, De Croos JN, Iu J, Hurtig M, Kandel RA, Theodoropoulos JS. Supplementation with platelet-rich plasma improves the *in vitro* formation of tissue-engineered cartilage with enhanced mechanical properties. *Arthroscopy* 2013; 29(10): 1685-92. <http://dx.doi.org/10.1016/j.arthro.2013.07.259> PMID: 24075614
- [55] van Buul GM, Koevoet WL, Kops N, *et al*. Platelet-rich plasma release inhibits inflammatory processes in osteoarthritic chondrocytes. *Am J Sports Med* 2011; 39(11): 2362-70. <http://dx.doi.org/10.1177/0363546511419278> PMID: 21856929
- [56] Burchard R, Huflage H, Soost C, Richter O, Bouillon B, Graw JA. Efficiency of platelet-rich plasma therapy in knee osteoarthritis does not depend on level of cartilage damage. *J Orthop Surg Res* 2019; 14(1): 153. <http://dx.doi.org/10.1186/s13018-019-1203-0> PMID: 31126348
- [57] Raeissadat SA, Ghorbani E, Sanei Taheri M, *et al*. MRI changes after platelet rich plasma injection in knee osteoarthritis (randomized clinical trial). *J Pain Res* 2020; 13(1): 65-73. <http://dx.doi.org/10.2147/JPR.S204788> PMID: 32021396
- [58] Halpern B, Chaudhury S, Rodeo SA, *et al*. Clinical and MRI outcomes after platelet-rich plasma treatment for knee osteoarthritis. *Clin J Sport Med* 2013; 23(3): 238-9. <http://dx.doi.org/10.1097/JSM.0b013e31827c3846> PMID: 23238250
- [59] Raeissadat SA, Hosseini GP, Bahrami MH, *et al*. The Comparison effects of intra-articular injection of Platelet-Rich Plasma (PRP), Plasma Rich in Growth Factor (PRGF), Hyaluronic Acid (HA), and ozone in knee osteoarthritis: A one year randomized clinical trial. *Ann Rheum Dis* 2020; 79(S1): 1744-5.
- [60] Di Martino A, Di Matteo B, Papio T, *et al*. Platelet-rich plasma *versus* hyaluronic acid injections for the treatment of knee osteoarthritis: Results at 5 years of a double-blind, randomized controlled trial. *Am J Sports Med* 2019; 47(2): 347-54. <http://dx.doi.org/10.1177/0363546518814532> PMID: 30545242
- [61] Karasavvidis T, Totlis T, Gilat R, Cole BJ. Platelet-rich plasma combined with hyaluronic acid improves pain and function compared with hyaluronic acid alone in knee osteoarthritis: A systematic review and meta-analysis. *Arthroscopy* 2021; 37(4): 1277-1287.e1. <http://dx.doi.org/10.1016/j.arthro.2020.11.052> PMID: 33278533
- [62] Altamura SA, Di Martino A, Andriolo L, *et al*. Platelet-rich plasma for sport-active patients with knee osteoarthritis: Limited return to sport. *BioMed Res Int* 2020; 2020: 8243865. Available from: <https://www.hindawi.com/journals/bmri/2020/8243865/> <http://dx.doi.org/10.1155/2020/8243865> PMID: 32076616
- [63] Su K, Bai Y, Wang J, Zhang H, Liu H, Ma S. Comparison of hyaluronic acid and PRP intra-articular injection with combined intra-articular and intraosseous PRP injections to treat patients with knee osteoarthritis. *Clin Rheumatol* 2018; 37(5): 1341-50. <http://dx.doi.org/10.1007/s10067-018-3985-6> PMID: 29388085
- [64] Lin KY, Yang CC, Hsu CJ, Yeh ML, Renn JH. Intra-articular injection of platelet-rich plasma is superior to hyaluronic acid or saline solution in the treatment of mild to moderate knee osteoarthritis: A randomized, double-blind, triple-parallel, placebo-controlled clinical trial. *Arthroscopy* 2019; 35(1): 106-17. <http://dx.doi.org/10.1016/j.arthro.2018.06.035> PMID: 30611335
- [65] Rai SK, Raman VP, Rohit V, Wani SS. Combined intra-articular injections (Hyaluronic acid, platelet-rich plasma, and corticosteroid) for osteoarthritis knee, an effective alternative treatment. *J Orthop Trauma Rehabil* 2018; 10(1): 57-60. http://dx.doi.org/10.4103/jotr.jotr_7_17
- [66] Dhillon MS, Patel S, Bansal T. Improving PRP for use in osteoarthritis knee- upcoming trends and futuristic view. *J Clin Orthop Trauma* 2019; 10(1): 32-5. <http://dx.doi.org/10.1016/j.jcot.2018.10.005> PMID: 30705528
- [67] Mohiuddin AKM, Lewis P, Choudhury KN, Sadiq BU. Clinical outcome of photoactivated platelet-rich plasma in the treatment of knee osteoarthritis. *Rheumatol Orthop Med* 2018; 4(1): 1-4.
- [68] Badr ME, Hafez EA, Atif EG, El-Sayed Heba M. Intra-articular injection of platelet-rich plasma and therapeutic exercise in knee osteoarthritis. *Egypt Rheumatol Rehabil* 2019; 46(1): 1-10. http://dx.doi.org/10.4103/err.err_22_18
- [69] O'Connell B, Wragg NM, Wilson SL. The use of PRP injections in the management of knee osteoarthritis. *Cell Tissue Res* 2019; 376(2): 143-52. <http://dx.doi.org/10.1007/s00441-019-02996-x> PMID: 30758709
- [70] Platelet-rich plasma injections for osteoarthritis of the knee, Inc. Available from: <https://www.nice.org.uk/guidance/IPG637>
- [71] Robinson K. EULAR Issues Recommendations for Knee OA Platelet-Rich Plasma Injections. 2020. Available from: <https://www.rheumatologynetwork.com/view/eular-issues-recommendations-knee-oa-platelet-rich-plasma-injections> Accessed on 29 June, published on 11 June, 2020.
- [72] Shahid M, Kundra R. Platelet-Rich Plasma (PRP) for knee disorders. *EFORT Open Rev* 2017; 2(1): 28-34. <http://dx.doi.org/10.1302/2058-5241.2.160004> PMID: 28607768
- [73] Manchikanti L, Centeno CJ, Atluri S, *et al*. Bone Marrow Concentrate (BMC) therapy in musculoskeletal disorders: evidence-based policy position Statement of American Society of Interventional Pain Physicians (ASIPP). *Pain Physician* 2020; 23(2): E85-E131. PMID: 32214287
- [74] Gong J, Fairley J, Cicuttini FM, *et al*. Effect of stem cell injections on osteoarthritis-related structural outcomes - a systematic review. *J Rheumatol* 2021; 48(4): 585-97. <http://dx.doi.org/10.3899/jrheum.200021> PMID: 33004537
- [75] Chahal J, Gómez-Aristizábal A, Shestopaloff K, *et al*. Bone marrow mesenchymal stromal cell treatment in patients with osteoarthritis results in overall improvement in pain and symptoms and reduces synovial inflammation. *Stem Cells Transl Med* 2019; 8(8): 746-57. PMID: 30964245
- [76] Freitag J, Bates D, Wickham J, *et al*. Adipose-derived mesenchymal stem cell therapy in the treatment of knee osteoarthritis: A randomized controlled trial. *Regen Med* 2019; 14(3): 213-30. <http://dx.doi.org/10.2217/rme-2018-0161> PMID: 30762487
- [77] Gobbi A, Whyte GP. Long-term clinical outcomes of one-stage cartilage repair in the knee with hyaluronic acid-based scaffold embedded with mesenchymal stem cells sourced from bone marrow aspirate concentrate. *Am J Sports Med* 2019; 47(7): 1621-8. <http://dx.doi.org/10.1177/0363546519845362> PMID: 31095402
- [78] Jo CH, Lee YG, Shin WH, *et al*. Intra-articular injection of mesenchymal stem cells for the treatment of osteoarthritis of the knee: A proof-of-concept clinical trial. *Stem cell* 2014; 32(5): 1254-66. <http://dx.doi.org/10.1002/stem.1634>
- [79] Hernigou P, Delambre J, Quiennec S, Poignard A. Human bone marrow mesenchymal stem cell injection in subchondral lesions of knee osteoarthritis: A prospective randomized study *versus* contralateral arthroplasty at a mean fifteen year follow-up. *Int Orthop* 2021; 45(2): 365-73. <http://dx.doi.org/10.1007/s00264-020-04571-4> PMID: 32322943
- [80] Song JS, Hong KT, Kim NM, *et al*. Cartilage regeneration in osteoarthritic knees treated with distal femoral osteotomy and intra-lesional implantation of allogenic human umbilical cord blood-derived mesenchymal stem cells: A report of two cases. *Knee* 2019; 26(6): 1445-50. <http://dx.doi.org/10.1016/j.knee.2019.07.017> PMID: 31443940
- [81] Matas J, Orrego M, Amenabar D, *et al*. Umbilical cord-derived Mesenchymal Stromal Cells (MSCs) for knee osteoarthritis: Repeated MSC dosing is superior to a Single MSC dose and to hyaluronic acid in a controlled randomized phase I/II trial. *Stem Cells Transl Med* 2019; 8(3): 215-24.

- [82] <http://dx.doi.org/10.1002/sctm.18-0053> PMID: 30592390
Xing D, Wu J, Wang B, *et al.* Intra-articular delivery of umbilical cord-derived mesenchymal stem cells temporarily retard the progression of osteoarthritis in a rat model. *Int J Rheum Dis* 2020; 23(6): 778-87.
- [83] <http://dx.doi.org/10.1111/1756-185X.13834> PMID: 32319197
Geng Y, Chen J, Alahdal M, *et al.* Intra-articular injection of hUC-MSCs expressing miR-140-5p induces cartilage self-repairing in the rat osteoarthritis. *J Bone Miner Metab* 2020; 38(3): 277-88.
- [84] <http://dx.doi.org/10.1007/s00774-019-01055-3> PMID: 31760502
Zhu Y, Wang Y, Zhao B, *et al.* Comparison of exosomes secreted by induced pluripotent stem cell-derived mesenchymal stem cells and synovial membrane-derived mesenchymal stem cells for the treatment of osteoarthritis. *Stem Cell Res Ther* 2017; 8(1): 64.
- [85] <http://dx.doi.org/10.1186/s13287-017-0510-9> PMID: 28279188
Hsu CC, Cheng JH, Wang CJ, Ko JY, Hsu SL, Hsu TC. Shock-wave therapy combined with autologous adipose-derived mesenchymal stem cells is better than with human umbilical cord Wharton's jelly-derived mesenchymal stem cells on knee osteoarthritis. *Int J Mol Sci* 2020; 21(4): 1217.
- [86] <http://dx.doi.org/10.3390/ijms21041217> PMID: 32059379
Jevotovsky DS, Alfonso AR, Einhorn TA, Chiu ES. Osteoarthritis stem cell therapy in humans: A systematic review. *Osteoarthritis Cartilage* 2018; 26(6): 711-29.
- [87] <http://dx.doi.org/10.1016/j.joca.2018.02.906> PMID: 29544858
Songa Y, Zhanga J, Xua H, *et al.* Mesenchymal stem cells in knee osteoarthritis treatment: A systematic review and meta-analysis. *J orthop Transl* 2020; 24: 121-30.
- [88] Ni Z, Zhou S, Li S, *et al.* Exosomes: Roles and therapeutic potential in osteoarthritis. *Bone Res* 2020; 8: 25.
- [89] <http://dx.doi.org/10.1038/s41413-020-0100-9>
Ni Z, Kuang L, Chen H, *et al.* The exosome-like vesicles from osteoarthritic chondrocyte enhanced mature IL-1 β production of macrophages and aggravated synovitis in osteoarthritis. *Cell Death Dis* 2019; 10(7): 522.
- [90] <http://dx.doi.org/10.1038/s41419-019-1739-2> PMID: 31285423
Zhou Q, Cai Y, Jiang Y, Lin X. Exosomes in osteoarthritis and cartilage injury: Advanced development and potential therapeutic strategies. *Int J Biol Sci* 2020; 16(11): 1811-20.
- [91] <http://dx.doi.org/10.7150/ijbs.41637> PMID: 32398951
Nummenmaa E, Hamalainen M, Moilanen T, Vuolteenaho K, Moilanen E. Effects of fibroblast growth factor-2 and its receptor antagonists in osteoarthritis. *Osteoarthr cartil* 2015; 23(S2): A269.
- [92] <http://dx.doi.org/10.1016/j.joca.2015.02.490>
Li R, Wang B, He CQ, *et al.* Upregulation of fibroblast growth factor 1 in the synovial membranes of patients with late stage osteoarthritis. *Genet Mol Res* 2015; 14(3): 11191-9.
- [93] <http://dx.doi.org/10.4238/2015.September.22.13> PMID: 26400350
Honsawek S, Yuktanandana P, Tanavalee A, Saetan N, Anomasiri W, Parkpian V. Correlation between plasma and synovial fluid basic fibroblast growth factor with radiographic severity in primary knee osteoarthritis. *Int Orthop* 2012; 36(5): 981-5.
- [94] <http://dx.doi.org/10.1007/s00264-011-1435-z> PMID: 22173563
Li ZC, Xiao J, Wang G, *et al.* Fibroblast growth factor-21 concentration in serum and synovial fluid is associated with radiographic bone loss of knee osteoarthritis. *Scand J Clin Lab Invest* 2015; 75(2): 121-5.
- [95] <http://dx.doi.org/10.3109/00365513.2014.992942> PMID: 25549692
Zhu L, Weng Z, Shen P, *et al.* S100B regulates inflammatory response during osteoarthritis via fibroblast growth factor receptor 1 signaling. *Mol Med Rep* 2018; 18(6): 4855-64.
- [96] <http://dx.doi.org/10.3892/mmr.2018.9523> PMID: 30280200
Lohmander LS, Hellot S, Dreher D, *et al.* Intraarticular sprifermin (recombinant human fibroblast growth factor 18) in knee osteoarthritis: A randomized, double-blind, placebo-controlled trial. *Arthritis Rheumatol* 2014; 66(7): 1820-31.
- [97] <http://dx.doi.org/10.1002/art.38614> PMID: 24740822
Hochberg MC, Guermazi A, Guehring H, *et al.* Effect of intra-articular sprifermin vs. placebo on femorotibial joint cartilage thickness in patients with osteoarthritis: The FORWARD randomized clinical Trial. *JAMA* 2019; 322(14): 1360-70.
- [98] <http://dx.doi.org/10.1001/jama.2019.14735> PMID: 31593273
Zeng N, Chen XY, Yan ZP, Li JT, Liao T, Ni GX. Efficacy and safety of sprifermin injection for knee osteoarthritis treatment: A meta-analysis. *Arthritis Res Ther* 2021; 23(1): 107.
- [99] <http://dx.doi.org/10.1186/s13075-021-02488-w> PMID: 33836824
Joosten LA, Helsen MMA, Saxne T, van De Loo FA, Heinegard D, van Den Berg WB. IL-1 alpha beta blockade prevents cartilage and bone destruction in murine type II collagen-induced arthritis, whereas TNF-alpha blockade only ameliorates joint inflammation. *J Immunol* 1999; 163(9): 5049-55.
- [100] PMID: 10528210
Ismail HM, Miotla-Zarebska J, Troeberg L, *et al.* JNK-2 controls aggrecan degradation in murine articular cartilage and the development of experimental osteoarthritis. *Arthritis Rheumatol* 2016; 68(5): 1165-71.
- [101] PMID: 26663140
Jiang Y, Genant HK, Watt I, *et al.* A multicenter, double-blind, dose-ranging, randomized, placebo-controlled study of recombinant human interleukin-1 receptor antagonist in patients with rheumatoid arthritis: Radiologic progression and correlation of Genant and Larsen scores. *Arthritis Rheum* 2000; 43(5): 1001-9.
- [102] [http://dx.doi.org/10.1002/1529-0131\(200005\)43:5<1001::AID-ANR7>3.0.CO;2-P](http://dx.doi.org/10.1002/1529-0131(200005)43:5<1001::AID-ANR7>3.0.CO;2-P) PMID: 10817552
Fraenkel L, Roubenoff R, LaValley M, *et al.* The association of peripheral monocyte derived interleukin 1beta (IL-1beta), IL-1 receptor antagonist, and tumor necrosis factor-alpha with osteoarthritis in the elderly. *J Rheumatol* 1998; 25(9): 1820-6.
- [103] PMID: 9733466
Cohen SB, Proudman S, Kivitz AJ, *et al.* A randomized, double-blind study of AMG 108 (a fully human monoclonal antibody to IL-1R1) in patients with osteoarthritis of the knee. *Arthritis Res Ther* 2011; 13(4): R125.
- [104] <http://dx.doi.org/10.1186/ar3430> PMID: 21801403
Lacy SE, Wu C, Ambrosi DJ, *et al.* Generation and characterization of ABT-981, a dual variable domain immunoglobulin (D-VD-Ig(TM)) molecule that specifically and potently neutralizes both IL-1 α and IL-1 β . *MAbs* 2015; 7(3): 605-19.
- [105] <http://dx.doi.org/10.1080/19420862.2015.1026501> PMID: 25764208
Ridker PM, Everett BM, Thuren T, *et al.* Antiinflammatory therapy with canakinumab for atherosclerotic disease. *N Engl J Med* 2017; 377(12): 1119-31.
- [106] <http://dx.doi.org/10.1056/NEJMoa1707914> PMID: 28845751
Schieker M, Conaghan PG, Mindeholm L, *et al.* Effects of interleukin-1 β inhibition on incident hip and knee replacement: Exploratory analyses from a randomized, double-blind, placebo-controlled trial. *Ann Intern Med* 2020; 173(7): 509-15.
- [107] <http://dx.doi.org/10.7326/M20-0527> PMID: 32744862
Marchetti C, Swartzwelder B, Gamboni F, *et al.* OLT1177, a β -sulfonyl nitrile compound, safe in humans, inhibits the NLRP3 inflammasome and reverses the metabolic cost of inflammation. *Proc Natl Acad Sci USA* 2018; 115(7): E1530-9.
- [108] <http://dx.doi.org/10.1073/pnas.1716095115> PMID: 29378952
Vincent TL. IL-1 in osteoarthritis: time for a critical review of the literature. *F1000 Res* 2019; 8: F1000 Faculty Rev-934.
- [109] <http://dx.doi.org/10.12688/f1000research.18831.1> PMID: 31249675
Evans CH, Ghivizzani SC, Robbins PD. Arthritis gene therapy approved in Korea. *J Am Acad Orthop Surg* 2018; 26(2): e36-8.
- [110] <http://dx.doi.org/10.5435/JAAOS-D-17-00695> PMID: 29303924
Kim MK, Ha CW, In Y, *et al.* A multicenter, double-blind, phase III clinical trial to evaluate the efficacy and safety of a cell and gene therapy in knee osteoarthritis patients. *Hum Gene Ther Clin Dev* 2018; 29(1): 48-59.
- [111] <http://dx.doi.org/10.1089/humc.2017.249> PMID: 29641281
Lee B. INVOSSA, a first-in-class of cell and gene therapy for osteoarthritis treatment: the phase III trial. *Osteoarthritis Cartilage* 2018; 26(7): S43-4.
- [112] <http://dx.doi.org/10.1016/j.joca.2018.02.103>
Saviola G, Ferrari P, Niccolò E, *et al.* Use of clodronate for painful knee prosthesis in osteoarthritis patients: A 6-month pilot study. *Minerva Med* 2020; 111(6): 551-9.
- [112] <http://dx.doi.org/10.23736/S0026-4806.20.06706-3> PMID:

- 32573517
- [113] Hayes KN, Giannakeas V, Wong AKO. Bisphosphonate use is protective of radiographic knee osteoarthritis progression among those with low disease severity and being non-overweight: Data from the osteoarthritis initiative. *J Bone Miner Res* 2020; 35(12): 2318-26.
<http://dx.doi.org/10.1002/jbmr.4133> PMID: 32662919
- [114] Xing RL, Zhao LR, Wang PM. Bisphosphonates therapy for osteoarthritis: A meta-analysis of randomized controlled trials. *Springerplus* 2016; 5(1): 1704.
<http://dx.doi.org/10.1186/s40064-016-3359-y> PMID: 27757376
- [115] Vaysbrot EE, Osani MC, Musetti MC, McAlindon TE, Bannuru RR. Are bisphosphonates efficacious in knee osteoarthritis? A meta-analysis of randomized controlled trials. *Osteoarthritis Cartilage* 2018; 26(2): 154-64.
<http://dx.doi.org/10.1016/j.joca.2017.11.013> PMID: 29222056
- [116] Cai G, Aitken D, Laslett LL, *et al.* Effect of intravenous zoledronic acid on tibiofemoral cartilage volume among patients with knee osteoarthritis with bone marrow lesions: A randomized clinical trial. *JAMA* 2020; 323(15): 1456-66.
<http://dx.doi.org/10.1001/jama.2020.2938> PMID: 32315057

DISCLAIMER: The above article has been published, as is, ahead-of-print, to provide early visibility but is not the final version. Major publication processes like copyediting, proofing, typesetting and further review are still to be done and may lead to changes in the final published version, if it is eventually published. All legal disclaimers that apply to the final published article also apply to this ahead-of-print version.