

Mechanochemical Endovenous Ablation of Small Saphenous Vein Insufficiency Using the ClariVein[®] Device: One-year Results of a Prospective Series

D. Boersma^{a,*}, R.R.J.P. van Eekeren^b, D.A.B. Werson^a, R.I.F. van der Waal^c, M.M.J.P. Reijnen^b, J.-P.P.M. de Vries^a

^a Department of Vascular Surgery, St. Antonius Hospital, Koekoekslaan 1, 3540CM Nieuwegein, The Netherlands

^b Department of Surgery, Rijnstate Hospital, Arnhem, The Netherlands

^c Department of Dermatology, St. Antonius Hospital, Nieuwegein, The Netherlands

WHAT THIS PAPER ADDS

This study is the first study showing feasibility, safety and efficaciousness of mechanochemical endovenous ablation (MOCA[™]) of small saphenous vein (SSV) insufficiency.

Objective: This study evaluated the feasibility, safety and 1-year results of mechanochemical endovenous ablation (MOCA[™]) of small saphenous vein (SSV) insufficiency.

Design: Prospective cohort study.

Materials and methods: Fifty consecutive patients were treated for primary SSV insufficiency with MOCA[™] using the ClariVein[®] device and polidocanol. Initial technical success, complications, patient satisfaction and visual analogue scale (VAS) pain score were assessed. Anatomic and clinical success was assessed at 6 weeks and at 1 year.

Results: Initial technical success of MOCA[™] was 100%. At the 6-week assessment, all treated veins were occluded. The 1-year follow-up duplex showed anatomic success in 94% (95% confidence interval, 0.87–1). Venous clinical severity score (VCSS) decreased significantly from 3.0 (interquartile range (IQR) 2–5) before treatment to 1.0 (IQR 1–3, $P < 0.001$) at 6 weeks and to 1.0 (IQR 1–2, $P < 0.001$) at 1 year. Median procedural VAS score for pain was 2 (IQR 2–4). No major complications were observed, especially no nerve injury.

Conclusions: MOCA[™] is a safe, feasible and efficacious technique for treatment of SSV insufficiency. One-year follow-up shows a 94% anatomic success rate and no major complications.

© 2012 European Society for Vascular Surgery. Published by Elsevier Ltd. All rights reserved.

Article history: Received 15 July 2012, Accepted 8 December 2012, Available online 9 January 2013

Keywords: Varicose veins, Saphenous vein, Varicose veins therapy, Polidocanol

Varicose veins are a common medical condition with an overall prevalence between 20% and 60%.¹ The effect of venous insufficiency on health-related quality of life is substantial and comparable with other chronic diseases such as arthritis, diabetes and cardiovascular disease.² These problems are mostly associated with insufficiency of great saphenous veins (GSVs); however, insufficiency of the small saphenous vein (SSV) is responsible in 15% of patients with varicose veins.³

Until the 1990s, high ligation, with or without surgical stripping, was the preferred option for venous insufficiency, although there was no standard in surgical treatment of SSV insufficiency. The introduction of minimally invasive endothermal catheter modalities, including endovenous laser ablation (EVLA) and radiofrequency ablation (RFA), has

revolutionised the treatment of varicose veins. These have become the preferred techniques, with high success rates.^{4,5}

Most endovenous ablation techniques are based on heating of the vein wall and, therefore, require the instillation of tumescent anaesthesia. Despite tumescent, thermal-associated complications, such as prolonged pain and skin burn, have been described. The risk of sural nerve injury is a major concern in surgical stripping and endovenous thermal ablation of the SSV.^{6–8} The main focus of improving therapy is currently aimed at reducing pain during and after treatment, as well as reducing heat-related trauma.

The recently introduced mechanochemical endovenous ablation (MOCA[™]) technique using the ClariVein[®] catheter (Vascular Insights, Madison, CT, USA) is unique: mechanical injury to the venous endothelium is combined with simultaneous catheter-guided infusion of a liquid sclerosant. No heat is generated and, therefore, tumescent is not required. Recent studies have proven that MOCA[™] is a feasible and

* Corresponding author. Tel.: +31 30 6093376; fax: +31 30 6036578.

E-mail address: doekeboersma@gmail.com (D. Boersma).

1078-5884/\$ – see front matter © 2012 European Society for Vascular Surgery. Published by Elsevier Ltd. All rights reserved.

<http://dx.doi.org/10.1016/j.jvs.2012.12.004>

safe treatment for GSV insufficiency.^{9,10} We aimed to evaluate the initial results and the 1-year follow-up of MOCA™ using the ClariVein® catheter in combination with polidocanol in SSV insufficiency.

MATERIALS AND METHODS

This study included all patients with symptomatic, primary SSV insufficiency treated in the St. Antonius Hospital, Nieuwegein, and the Rijnstate Hospital, Arnhem, The Netherlands, from June 2010 to April 2011. Physical examination was performed by a vascular surgeon or a vascular physician assistant before treatment, and the CEAP classification and venous clinical severity score (VCSS) were assessed. All patients underwent duplex ultrasonography (DUS) of the deep and superficial veins of the affected leg. SSV insufficiency was defined as a retrograde flow >0.5 s after calf compression while standing.

Inclusion criteria were age >18 years, duplex-confirmed SSV incompetence at sapheno-popliteal junction, long-segment SSV insufficiency (>10 cm), SSV diameter between 2.5 and 11 mm, C₂₋₆ E_P A_{S4} P_R and written informed consent. Exclusion criteria were previous surgical treatment of the SSV, history of ipsilateral deep vein thrombosis (DVT), ipsilateral GSV or deep venous insufficiency, peripheral arterial occlusive disease or use of anticoagulants. Patients with allergy, pregnancy or lactation or other contraindications for the use of polidocanol were excluded.

Ethical approval for research was granted.

Intervention:

All interventions were performed with the ClariVein® device, combined with polidocanol (Aethoxysklerol®, KreusslerPharma, Wiesbaden, Germany), by a vascular surgeon or a physician assistant on an outpatient basis. All physicians had previously performed >10 MOCA™ procedures using the ClariVein® in the GSV. No analgesia or antibiotics were administered before treatment.

The MOCA™ technique has been previously described.⁹ Briefly, the ClariVein® device is a disposable 2.6F single-lumen catheter for infusing liquid sclerosant. A metal wire, fitted distally with a small ball, runs through the catheter (Fig. 1). It is hypothesised that rotation of the wire

(3000 rpm) induces intimal injury and disperses the liquid sclerosant.

The entire length of the first 15 SSVs was treated with 1.5% polidocanol. In the later 35 cases, the proximal SSV (10–15 cm) was treated with 2 ml polidocanol (2%) and the remainder with polidocanol (1.5%). The protocol was altered because preliminary results in GSVs showed improved occlusion rates with the latter regimen. The total amount of used liquid sclerosant is noted in Table 1. In none of the patients the allowed daily dose of 2 mg kg⁻¹ day⁻¹ is exceeded. No concomitant phlebectomies were performed.

DUS was performed to confirm occlusion of treated vein. Patients wore compression stockings (30–40 mm Hg) continuously for the first 24 h and during the daytime for the next 2 weeks. Patients were allowed to perform their daily activities immediately. No standard analgesics were prescribed.

Outcomes and follow-up protocol

The primary outcome measures were (1) technical success, defined as the ability to perform procedure as planned and achieve immediate occlusion after the procedure, and (2) anatomic success, defined as occlusion of treated vein. A re-canalised SSV or treatment failure was defined as an open segment of >10 cm.¹¹

Secondary outcomes included complications, treatment time, patient satisfaction and procedural pain.

The treatment time (from start of procedure to applying compression stocking) and length of the treated vein were noted. Patients were asked to record the level of pain during treatment on a visual analogue scale (VAS) from 0 cm (no pain) to 10 cm (worst imaginable pain). All patients were scheduled for a follow-up assessment at 6 weeks and 1 year by a vascular surgeon, including physical examination, determination of VCSS and DUS. After 6 weeks, patients were asked to quantify their satisfaction of the treatment in a 10-point score. In the case of residual varicosities, sclerotherapy was offered. Any postprocedural complications were noted. All data were gathered prospectively and stored in computerised database.

Statistical analysis

Variables are presented as mean with standard deviation (SD) or range for parametric continuous outcomes, as

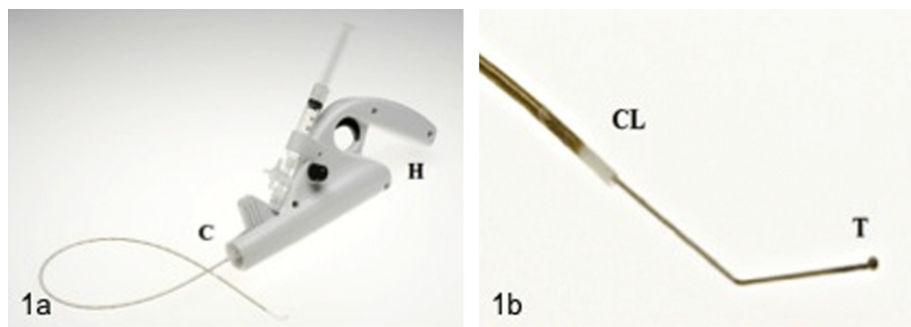


Figure 1. a: ClariVein® device consists of motor handle unit (H) and infusion catheter (C). b: Dispersion tip (T) protrudes with angulated tip from catheter (CL). Acknowledgement: Figure A is reproduced with permission from the Journal of Endovascular Therapy.¹⁴ Copyright 2011. International Society of Endovascular Specialists.

Table 1. Patient demographics and treatment characteristics.

Number of patients ^a	50 (100%)
Bilateral SSV insufficiency	None
Age ^b (years)	53 (25–84)
Male ^a	18 (36%)
Female ^a	32 (64%)
Weight ^b (kg)	76 (48–135)
Dosage of polidocanol 1.5% ^a	15 (30%)
Dosage of polidocanol 2.0 mL 2%/1.5% ^a	35 (70%)
C ₂ Varicose veins ^a	26 (52%)
C ₃ Oedema ^a	14 (28%)
C ₄ Skin changes ^a	8 (16%)
C ₅ Healed ulcer ^a	1 (2%)
C ₆ Active ulcer ^a	1 (2%)
SSV diameter ^c (mm)	4.8 (3.5–7)
Length of treated SSV ^c (cm)	22 (18–35)
Total volume of polidocanol ^d (mL)	4.4 (±1.1)
Total dosage of polidocanol ^d (mg)	72 (±19)
Duration of treatment (min) ^c	20 (15–24)

^a Number (percentage of total).

^b Mean value (range).

^c Median value (interquartile range).

^d Mean value (SD). SSV, small saphenous vein.

median with IQR for non-parametric continuous outcomes and as frequencies and percentages for categoric variables. Kaplan–Meier survival analysis was used to assess anatomic success rate. The log-rank test was used to compare anatomic success between the initial protocol using 1.5% polidocanol and the latter protocol using the higher dosage. Change in VCSS was analysed with the Wilcoxon signed rank test. Statistical analyses were performed using Statistical Package for the Social Sciences (SPSS) 19.0 software (SPSS Inc, Chicago, IL, USA). A value of $P < 0.05$ was considered significant.

RESULTS

The study included 50 consecutive patients who met the eligibility criteria. Patient characteristics are described in Table 1. At 1 year, three patients (6%) were lost to follow-up: one was free of complaints and refused follow-up, and the other two did not respond to repeated invitations for the follow-up assessment.

Occlusion rates

The technical success rate was 100%: all treated SSVs were occluded on DUS directly after MOCA[®]. At 6 weeks, all treated veins (50 of 50) remained occluded. In 9 patients (18%) residual varicosities were treated by sclerotherapy to optimise cosmetic outcome.

At 1 year, 44 of 47 SSVs were occluded, for an anatomic success of 94% (95% confidence interval (CI), 0.87–1). Patients who were lost to follow-up were censored at 6 weeks after treatment. At the 1-year follow-up, re-canalisation occurred in 2 of the 15 patients treated with low-dose polidocanol (anatomic success, 87%; 95%CI, 0.71–1)

and in 1 of 32 patients who received the elevated dose of polidocanol (anatomic success, 97%; 95%CI, 0.91–1). The difference between these subgroups was not significant ($P = 0.187$).

Pain, patient satisfaction and duration of treatment

The median VAS pain score during treatment was 2 cm (IQR 2–4 cm). The median duration of treatment was 20 min (IQR 15–24 min). After 6 weeks, median patient satisfaction of the treatment was 8 (IQR 8–9).

Venous clinical severity score

At the 6-week follow-up, median VCSS had decreased significantly from 3 (IQR 2–5) pre-MOCA to 1 (IQR 1–3; $P < 0.001$). At 1 year after treatment, VCSS remained significantly decreased compared with preprocedural scores (1 (IQR 1–2), $P < 0.001$).

Complications

No major complications were observed. Importantly, there were no signs of any nerve injury, and no DVT, skin necrosis, infection or hyperpigmentation was recorded. Minor complications included localised ecchymosis (12%), induration around the access site (12%) and transient superficial thrombophlebitis of the treated vein (14%). Pain lasted longer than 1 week in 5 patients (10%), all caused by superficial thrombophlebitis. After 6 weeks and 1 year, no additional complications were seen.

DISCUSSION

This study is the first describing results of MOCA[™] in treating SSV insufficiency. Technical success was 100%, and after 6 weeks of follow-up, no re-canalisation was noticed. At the 1-year follow-up, anatomic success persisted in 44 of 47 patients (94%). An important observation was the difference in anatomic success between the initial group treated with 1.5% polidocanol and the later group treated with 2% polidocanol in the proximal section. Although this difference is not significant, probably because of the small number of patients, an elevated dosage of liquid sclerosant may be a key in optimising occlusion rates in MOCA[™].

The treatment of superficial venous insufficiency has changed dramatically in the last decade. Ligation, with or without surgical stripping, of insufficient saphenous veins has mostly been replaced by thermal endovenous catheter therapies, due to their superior efficacy and less invasive character.¹² Results of EVLA for SSV insufficiency have repeatedly been described, with short-term occlusion rates ranging from 91% to 100%.^{6,7,13,14} RFA in treatment of varicosity of the SSV has only been described in a small series, but shows excellent results.¹⁵

Ultrasound-guided foam sclerotherapy (UGFS) is another widely used minimally invasive technique to ablate varicose veins. Success rates of UGFS in SSV are 82% after a mean follow-up of 11 months. Although liquid sclerotherapy is

effective in treating reticular and spider veins, it should not be used to treat insufficiency of saphenous veins, due to inferior occlusion rates of 17%–60% at 1 year.^{4,11,16,17}

Two studies describing the safety and the initial results of MOCA™ were recently published. Elias et al. showed an occlusion rate in GSV of 96.7% after MOCA™ using sodium tetradecyl sulphate (Sotradecol®, AngioDynamics, Queensbury, NY, USA) after average follow-up of 260 days. MOCA™ combining ClariVein® with polidocanol showed occlusion in 97% of treated GSV at 6 weeks after treatment, and partial re-canalisation was described in 10%. No major complications occurred, and minor complains were acceptable in amount and severity.^{9,10}

All modalities in the treatment of varicose veins have specific complications. Ecchymosis and postprocedural pain seem inherent to heat-based therapies. In GSV, MOCA™ is associated with significantly less postoperative pain compared with RFA.¹⁸ More importantly, in SSV treatment, the anatomic proximity of the sural nerve poses an additional risk. In published data, transient sural nerve injury caused by ELVA varies between 1.3% and 11%.^{6,11,14,19} In redo SSV surgery, the incidence of numbness 1 year after treatment is as high as 28%.²⁰ In general, major complications, such as skin burns, DVT and pulmonary embolism after EVLA, seldom occur (<1%). Transient thrombophlebitis occurred in 14% of patients, comparable with foam sclerotherapy and RFA.¹¹ MOCA™ of the SSV has been proven to be safe: no major complications, including no sural nerve injuries, occurred. MOCA™ eliminates the need for tumescent anaesthesia, which can be desirable, because it is time-consuming and requires multiple injections.

Clinical results after endovenous ablation, in general, are excellent. In our study group, a significant decrease in VCSS was measured at 6 weeks and at 1 year of follow-up compared with preprocedural scores. Patient satisfaction was high.

One of the limitations of this study is that the maximum diameter of treated SSVs was 11 mm. The technical and clinical success of MOCA™ in larger-diameter varicose veins is still unknown. Pain scores during MOCA™ were very low. Postprocedural pain scores were not measured. Further controlled studies are required to compare pain with other techniques in SSV ablation. Patients on oral anticoagulants were excluded; thus, we cannot provide data on the effect of anticoagulant therapy on MOCA™. In contrast to endothermal therapy, anticoagulants might influence clot formation and lead to increased re-canalisation.

CONCLUSION

MOCA™ using the ClariVein® device and polidocanol appears to be a safe, feasible and efficacious technique in the treatment of SSV insufficiency. Early and 1-year follow-up results are promising, with a 94% occlusion rate, no major complications and low pain scores.

ACKNOWLEDGEMENT

The authors thank J.C. Kelder for his help with statistical analyses.

DISCLOSURE

JPPM de Vries is a consultant for Angiocare and MMPJ Reijnen for EMEDD.

CONFLICT OF INTEREST/FUNDING

None.

REFERENCES

- Callam MJ. Epidemiology of varicose veins. *Br J Surg* 1994;81:167–73.
- Andreozzi GM, Cordova RM, Scomparin A, Martini R, D'Erri A, Andreozzi F. Quality of Life Working Group on Vascular Medicine of SIAPAV. Quality of life in chronic venous insufficiency. An Italian pilot study of the Triveneto region. *Int Angiol* 2005;24:272–7.
- Almgren B, Eriksson E. Valvular incompetence in superficial, deep and perforator veins of limbs with varicose veins. *Acta Chirurg Scand* 1990;156:69–74.
- Van den Bos R, Arends L, Kockaert M, Neumann M, Nijsten T. Endovenous therapy of lower extremity varicosities: a meta-analysis. *J Vasc Surg* 2009;49:230–9.
- Darwood RJ, Theivacumar N, Dellagrammaticas D, Mavor AI, Gough MJ. Randomised clinical trial comparing endovenous laser ablation with surgery for the treatment of primary great saphenous varicose veins. *Br J Surg* 2008;95:294–301.
- Theivacumar NS, Beale RJ, Mavor AID, Gough MJ. Initial experience in endovenous laser ablation (EVLA) of varicose veins due to small saphenous vein reflux. *Eur J Vasc Endovasc Surg* 2007;33:614–8.
- Van den Bos RR, Neumann M, De Roos KP, Nijsten T. Endovenous laser ablation-induced complications: review of literature and new cases. *Dermatol Surg* 2009;35:1206–14.
- Sichlau MJ, Ryu RK. Cutaneous thermal injury after endovenous laser ablation of the great saphenous vein. *J Vasc Interv Radiol* 2004;15:865–7.
- Van Eekeren RRJP, Boersma D, Elias S, Holewijn S, Werson DAB, De Vries JPPM, et al. Endovenous mechanochemical ablation of great saphenous vein incompetence using the ClariVein device: a safety study. *J Endovasc Ther* 2011;18:328–34.
- Elias S, Raines JK. Mechanochemical tumescentless endovenous ablation: final results of the initial clinical trial. *Phlebology* 2012;27:67–72.
- Rasmussen LH, Lawaetz M, Bjoern L, Vennits B, Blemings A, Eklof B. Randomised clinical trial comparing endovenous laser ablation, radiofrequency ablation, foam sclerotherapy and surgical stripping for great saphenous varicose veins. *Br J Surg* 2011;98:1079–87.
- Tellings SS, Ceulen RPM, Sommer A. Surgery and endovenous techniques for the treatment of small saphenous varicose veins: a review of the literature. *Phlebology* 2011;26:179–84.
- Ravi R, Rodriguez-Lopez JA, Trayler EA, Barret DA, Ramaiah V, Diethrich EB. Endovenous ablation of incompetent saphenous veins: a large single-centre experience. *J Endovasc Ther* 2006;13:244–8.
- Gibson KD, Ferris BL, Polissar N, Neradilek B, Pepper D. Endovenous laser treatment of the small saphenous vein: efficacy and complications. *J Vasc Surg* 2007;45:795–803.
- Bisang U, Meier TO, Enzler M, Thalhammer C, Hussman M, Amann-Vesti BR. Results of endovenous ClosureFast treatment

- for varicose veins in an outpatient setting. *Phlebology* 2012 Apr;27(3):118–23.
- 16 Coleridge Smith P. Chronic venous disease treated by ultrasound guided foam sclerotherapy. *Eur J Vasc Endovasc Surg* 2006;31:577–83.
- 17 Hamel-Desnos C, Allaert FA. Liquid versus foam sclerotherapy. *Phlebology* 2009;24:240–6.
- 18 Van Eekeren RRJP, Boersma D, Konijn V, De Vries JPPM, Reijnen MMJP. Postoperative pain and early quality of life after radiofrequency ablation and mechanochemical endovenous ablation of incompetent great saphenous veins. *J Vasc Surg* 2012 [ePub ahead of print].
- 19 Park SJ, Yim SB, Cha DW, Kim SC, Lee SH. Endovenous laser treatment of the small saphenous vein with a 980-nm diode laser: early results. *Dermatol Surg* 2008;34:517–24.
- 20 O'Hare JL, Vandenbreock CP, Whitman B, Campbell B, Heather BP, Earnshaw JJ. A prospective evaluation of the outcome after small saphenous varicose vein surgery with one-year follow-up. *J Vasc Surg* 2008;48:669–73.