



# Sustainability of Individual EndoAnchor Implants in Therapeutic Use to Treat Type Ia Endoleak After Endovascular Aneurysm Repair

Kim van Noort, MSc<sup>1,2</sup>, Jenske J. M. Vermeulen, MSc<sup>1,2</sup>,  
 Seline R. Goudekting, MSc<sup>1,2</sup>, Kenneth Ouriel, MD<sup>3</sup>,  
 William D. Jordan Jr, MD<sup>4</sup>, Jean M. Panneton, MD<sup>5</sup>,  
 Cornelis H. Slump, MSc, PhD<sup>2</sup>, and Jean-Paul P.M. de Vries, MD, PhD<sup>6</sup>

## Abstract

**Purpose:** To investigate changes in penetration depths and angles of EndoAnchor implants with initially good penetration after therapeutic use in endovascular aneurysm repair. **Materials and Methods:** Patients were selected from the Aneurysm Treatment Using the Heli-FX Aortic Securement System Global Registry (ANCHOR; *ClinicalTrials.gov* identifier NCT01534819). Inclusion criteria were (1) EndoAnchor implantation to treat intraoperative or late type Ia endoleak and (2) at least 2 postoperative computed tomography angiography (CTA) scans. Exclusion criteria were the use of adjunct procedures. Based on these criteria, 54 patients (44 men) with 360 EndoAnchor implants were eligible for this analysis. Penetration depth of each EndoAnchor implant into the aortic wall was judged as (1) good ( $\geq 2$ -mm penetration), (2) borderline ( $< 2$  mm or when there was a gap between the endograft and the aortic wall), or (3) no penetration. The penetration depth and longitudinal angles of EndoAnchors with good penetration were investigated on the last available postprocedure CTA scan. Endoleaks were also analyzed. **Results:** EndoAnchor penetration on the first postprocedure CTA scan was good in 187 (51.9%), borderline in 69 (19.2%), and missing in 104 (28.9%). On the last CTA scan, 182 (97.4%) of the 187 initially well-positioned EndoAnchors remained good. Five (2.6%) EndoAnchors in 4 patients changed configuration over time (4 became borderline and 1 became nonpenetrating), all without any clinical sequelae. The median orthogonal angles of the EndoAnchor implants with good penetration on the first and last CTA scans were 92° [interquartile range (IQR) 85, 98] and 90° (IQR 84, 97), respectively ( $p=0.822$ ); for longitudinal angles, medians of 85° (IQR 71, 96) and 84° (IQR 70, 96) were found ( $p=0.043$ ). Of the 18 (33%) patients who had a type Ia endoleak on the first postprocedure CTA, 6 resolved over time. Median follow-up was 13 months, during which no new type Ia endoleak was found. **Conclusion:** Despite the small number of EndoAnchors analyzed, this study showed that the sustainability of EndoAnchor implants with initially good penetration is satisfactory at 1-year follow-up. The vast majority of EndoAnchor implants with good penetration initially remained in good position;  $< 3\%$  of implants became borderline or nonpenetrating, without any clinical consequence.

## Keywords

abdominal aortic aneurysm, endograft, endoleak, endovascular aneurysm repair, fixation, stent-graft

## Introduction

The Helix-FX EndoAnchor System (Medtronic Vascular, Santa Rosa, CA, USA) is designed to penetrate both the endograft fabric and aortic wall to ensure endograft fixation and seal in the infrarenal aortic neck during endovascular aneurysm repair (EVAR). EndoAnchor implants can be

used to treat intraoperative or late type Ia endoleaks in a therapeutic setting, and they can also prevent migration when used prophylactically.<sup>1–5</sup> Circumferential deployment approximates a surgical hand-sewn anastomosis if the EndoAnchors are successfully deployed.<sup>6–8</sup> Tassiopoulos et al<sup>9</sup> showed endotacking to be preventive for late neck dilatation.

A recent publication showed aortic neck diameter and neck calcium thickness as independent predictors for individual EndoAnchor implant failure<sup>10</sup>; therefore, careful planning is needed prior to deployment. An analysis of the penetration depth and angle of each EndoAnchor implant showed that a greater number of nonpenetrating EndoAnchor implants was associated with an increased risk for type Ia endoleaks, and 30% of EndoAnchors were deployed beyond the recommended use (ie, were positioned above the fabric, within thrombus, or below the aortic neck).<sup>11</sup> Besides deployment beyond the recommended use, technical positioning failure may cause the EndoAnchor implant not to intersect the aortic wall perpendicularly and therefore not completely penetrate the aortic wall. Moreover, penetration depth depends on the length of the EndoAnchor (4.5 mm) and aortic wall thickness for successful endotacking, with a maximum aortic wall thickness around 2 mm. These factors may also be important for the sustainability of the EndoAnchor implants in the aortic wall over time.

The aim of this study was to investigate changes in penetration depths and angles of EndoAnchor implants with initially good penetration over time and potential clinical sequelae of these alterations.

## Materials and Methods

### Patient Selection

Patients were selected from the dataset of the Aneurysm Treatment Using the Heli-FX Aortic Securement System Global Registry (ANCHOR; *ClinicalTrials.gov* identifier NCT01534819). Inclusion criteria for the current study sample were (1) EndoAnchor implantation to treat intraoperative or late type Ia endoleak and (2) at least 2 sequential postoperative contrast-enhanced computed tomography angiography (CTA) scans of good quality.

Patients with CTA scans with glue or metal artifacts were excluded, as were CTAs with slice thickness >3 mm. Patients with aortic cuffs were excluded because the sequence of the deployment of the additional material was unknown. Moreover, the extra layers cause substantial scatter, and the radial force of a double layer of endografts (main body and additional cuff) may influence the forces on the EndoAnchors and thus their position and any changes during follow-up. The study was conducted according to

the Declaration of Helsinki and informed consent was obtained for every registry patient.

In a prior study,<sup>11</sup> 86 patients were used to describe penetration depth and angles of EndoAnchor implants on the first postprocedure CTA scans. Thirty-two of these 86 patients did not have a subsequent CTA scan and were excluded, leaving 54 patients (44 men) in the current analysis. Fourteen (25.9%) patients (116 EndoAnchors) were treated for a revision of a type Ia endoleak, while 40 (74.1%) patients (244 EndoAnchor implants) received EndoAnchors to treat intraoperative type Ia endoleaks.

### Imaging Protocol and Assessments

Measurements were performed on the first CTA scan after EndoAnchor implantation and on the last available follow-up scan (or the last one before reintervention) on a 3Mensio vascular workstation (V9.0 SP1; Pie Medical Imaging BV, Maastricht, the Netherlands). A center lumen line (CLL) was semiautomatically drawn through the aortic lumen and adjusted manually if needed. Location of the orifices of the renal arteries, EndoAnchor implants, proximal endograft fabric markers, and aortic bifurcation were identified. The position and the angles of the EndoAnchors could be identified using the CLL and the renal orifice markings.<sup>11</sup>

A core laboratory (Syntactx, New York, NY) was used to measure the following anatomical characteristics on the first and last CTA scans: suprarenal aortic diameter, aortic diameter at the level of the lowest renal artery, proximal neck length (with a distal boundary where there was a 10% increase in the diameter at the level of the lowest renal artery), visual neck length, neck tortuosity index, maximum aneurysm sac diameter, suprarenal angulation, infrarenal angulation, neck thrombus thickness and circumference, and neck calcification thickness and circumference. Clinical outcomes in terms of endoleaks were assessed as no change (presence or absence of a type Ia endoleak on both follow-up scans); occurrence of type Ia endoleak between the 2 scans; or resolution of a type Ia endoleak after the first scan.

### EndoAnchor Analyses

According to a previous publication,<sup>10</sup> EndoAnchor implant penetration was judged to be (1) good when the EndoAnchor penetrated the endograft and  $\geq 2$  mm into the aortic wall,

<sup>1</sup>Department of Vascular Surgery, St Antonius Hospital, Nieuwegein, the Netherlands

<sup>2</sup>MIRA Institute of Biomedical Technology and Technical Medicine, University of Twente, Enschede, the Netherlands

<sup>3</sup>Syntactx, New York, NY, USA

<sup>4</sup>Department of Vascular Surgery, Emory University School of Medicine, Atlanta, GA, USA

<sup>5</sup>Division of Vascular Surgery, Eastern Virginia Medical School, Norfolk, VA, USA

<sup>6</sup>Department of Surgery, Division of Vascular Surgery, University Medical Centre Groningen, the Netherlands

### Corresponding Author:

Kim van Noort, Department of Vascular Surgery, St Antonius Hospital, Koekoekslaan 1, 3435 CM, Nieuwegein, the Netherlands.  
Email: kimvnoort@gmail.com

**Table 1.** Anatomical Characteristics of the Aorta on the First and Last Postprocedure Computed Tomography Scan.<sup>a</sup>

Anatomical Characteristics	First Scan	Last Scan	P
Suprarenal aortic diameter, mm	26.2 [24.7, 27.5]	25.7 [24.8, 27.6]	0.228
Aortic diameter at lowest renal artery, mm	25.5 [23.6, 27.8]	25.4 [23.9, 27.3]	0.472
Proximal neck length, mm	10.4 [6.5, 20.9]	11.0 [5.6, 19.6]	0.820
Maximum sac diameter, mm	59.3 [52.6, 69.1]	56.0 [49.0, 66.4]	<0.001
Suprarenal angulation, deg	13.0 [7.8, 19.5]	13.0 [8.0, 17.3]	0.102
Infrarenal angulation, deg	15.5 [7.8, 25.0]	14.0 [8.0, 21.3]	0.268
Neck thrombus average thickness, mm	0.0 [0.0, 0.0]	0.0 [0.0, 0.0]	0.514
Neck thrombus circumference, mm	0.0 [0.0, 0.0]	0.0 [0.0, 0.0]	0.594
Neck calcium average thickness, mm	0.0 [0.0, 0.0]	0.0 [0.0, 0.0]	0.833
Neck calcium circumference, mm	0.0 [0.0, 0.0]	0.0 [0.0, 0.0]	0.528

<sup>a</sup>Data represented as median [interquartile range: Q1, Q3].

(2) borderline when the EndoAnchor penetrated the endograft but <2 mm into the aortic wall or when there was a gap between the endograft and the aortic wall, or (3) no penetration at all.

Changes in EndoAnchor penetration status over time were analyzed for the EndoAnchors having good penetration on the first CTA scan. A previous study showed that EndoAnchor implants with borderline penetration are comparable in clinical outcome to nonpenetrating EndoAnchor implants.<sup>10</sup> Thus, both borderline and nonpenetrating EndoAnchors would not increase seal between the endograft and aortic wall and would never change to good penetration. The measurements were performed independently by 2 experienced observers (K.N., J.V.). A third observer opinion (J.P.dV) was requested if the outcome was inconclusive.

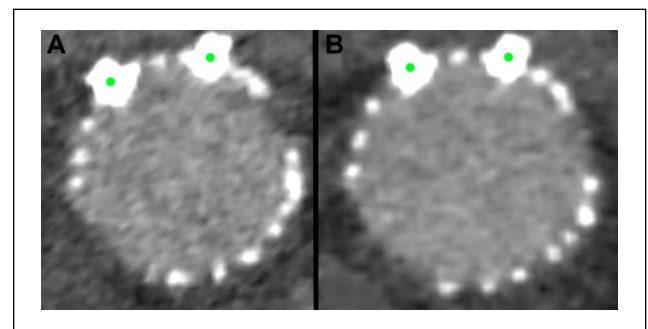
The orthogonal and longitudinal penetration angles were measured according to the validated method previously described in the study of Goudekettig et al.<sup>11</sup> Differences between the orthogonal and longitudinal angles over time were analyzed.

### Statistical Analysis

Since normality of data could not be assumed based on the Shapiro-Wilk test, data are presented as the median [interquartile range (IQR): Q1, Q3]. Differences between variables were tested with the Mann-Whitney *U* test. P-values were considered significant when 2-tailed  $\alpha < 0.05$ . Statistical analyses were performed with SPSS software (version 24; IBM Corp, Armonk, NY, USA).

### Results

A total of 360 EndoAnchor implants were deployed [median 6 per patient (IQR 4, 9)]; no double rows of EndoAnchors were used. Median time between the EVAR procedure and the first postprocedure CTA scan was 34 days (IQR 24, 43); for

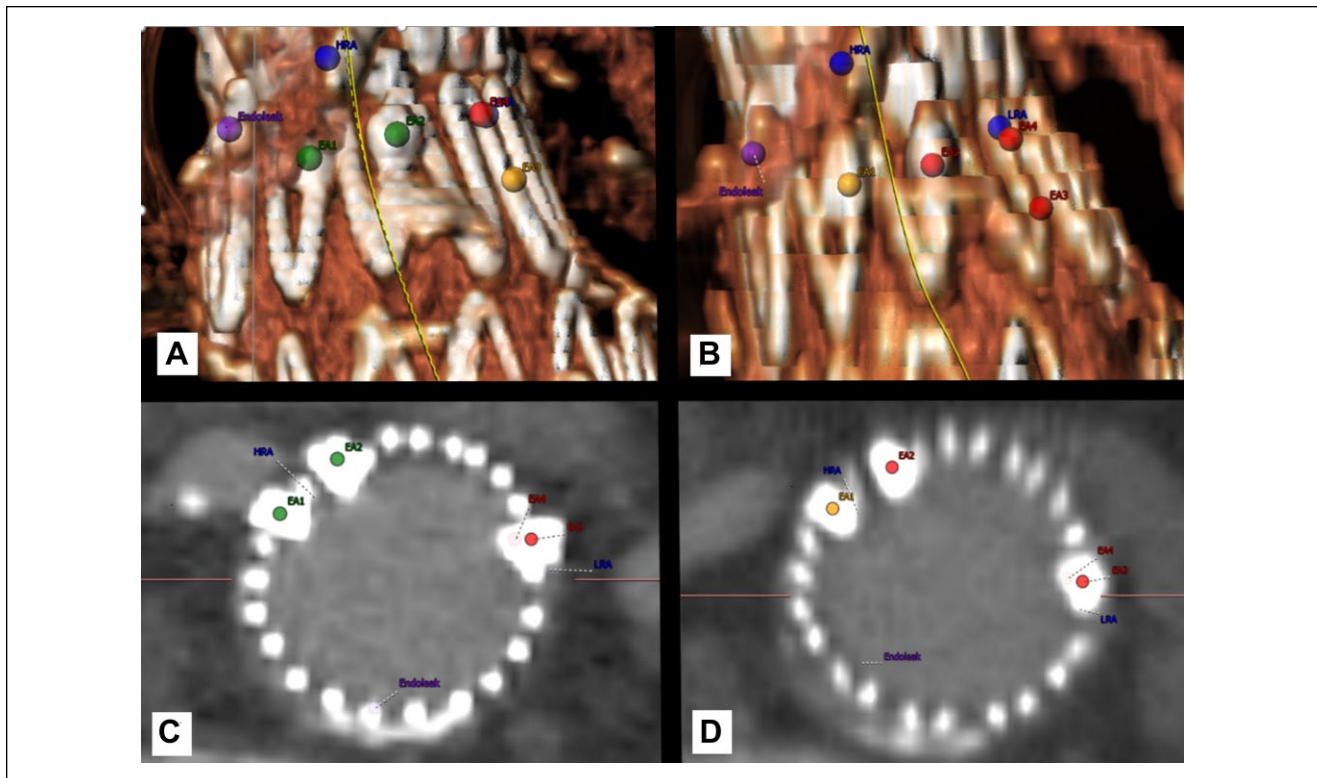


**Figures 1.** An example of stable EndoAnchor implants. (A) One-month postprocedure computed tomography angiography (CTA). A total of 6 EndoAnchor implants were positioned in this patient, but on this axial slice only 2 (green dots) are visible, both are penetrating the aortic wall as were the other 4 EndoAnchor implants (not visible). (B) Postprocedure CTA scan at 13 months. All EndoAnchor implants remain unchanged (green dots + 4 EndoAnchor implants that are not visible on this image).

the last scan the median interval was 13 months (IQR 8, 23). Between the first and most recent CTA scan (Table 1), maximum sac diameter became significantly smaller ( $p < 0.001$ ); other anatomical characteristics remained unchanged.

### EndoAnchor Penetration Analysis

EndoAnchor penetration on the first postprocedure CTA scan was good in 187 (51.9%), borderline in 69 (19.2%), and missing in 104 (28.9%). The 2 observers were not in agreement on 38 (20.3%) EndoAnchor implants; consensus was found with the third observer. Per patient, a median of 4 (IQR 2, 5) EndoAnchors had good penetration, which accounted for 53% (IQR 27, 80) of the EndoAnchors per patient. On the last CTA scan, 182 (97.4%) of the 187 EndoAnchors initially well positioned continued to show good penetration after follow-up (Figure 1). Five (2.6%) EndoAnchors in 4 patients changed configuration over time



**Figure 2.** (A, B) Three-dimensional and (C, D) axial views of the distribution of EndoAnchor implants at the (A, C) 30-day and the (B, D) 11-month computed tomography angiography scans. Good, borderline, and nonpenetrating EndoAnchor implants are visualized as green, orange, and red dots, respectively. EA1 and EA2 became borderline and nonpenetrating, respectively, at the 11-month follow-up. Note that only 4 EndoAnchors had been implanted, unevenly divided around the aortic neck. The purple dot represents the location of the endoleak and the blue dots represent the locations of the highest and lowest renal arteries (HRA and LRA, respectively).

(4 became borderline and 1 became nonpenetrating), all without any clinical sequelae.

Figure 2 and Table 2 show a patient in whom 1 EndoAnchor became borderline and 1 became nonpenetrating. In this case, only 4 EndoAnchors were initially deployed in the aortic neck, instead of the recommended use of at least 6. On both CTA scans a type Ia endoleak was visible. The neck had a conical shape and was only 3.2 mm in length, which is beyond the recommended use for standard EVAR with EndoAnchor implants. During follow-up, dilatation of the aortic neck created a growing gap of malapposition between the aortic wall and endograft, drawing the EndoAnchors away from the wall.

Figure 3 and Table 3 show another patient with a change in penetration depth of 1 EndoAnchor after 34 months of follow-up. Interestingly, only 2 of 11 EndoAnchor implants had good penetration at the first postprocedure CT scan; on the last CTA, 1 of the 2 became borderline. The endograft was initially deployed low, and there was a type Ia endoleak visible on both CTA scans. This challenging neck had a large calcium load at the location of the type Ia endoleak; consequently, no EndoAnchors were penetrating the aortic

wall at this location. Moreover, there was a gap between the aortic wall and endograft that could not be resolved with EndoAnchors. One of the 2 initially successful EndoAnchors became borderline because the aneurysm sac extended cranially, widening the gap between the fabric and aortic wall at the location of the EndoAnchor implant. Dilatation of the aortic neck may not be stopped by just 1 EndoAnchor with good penetration but may need more, as suggested in a prior publication.<sup>9</sup>

The remaining 2 EndoAnchors became borderline at 13 and 38 months, respectively. In 1 patient, 10 EndoAnchors were positioned, of which 3 had good penetration, 1 was borderline, and 6 had no penetration on the first CTA scan. There was no type Ia endoleak visible on either follow-up scan, and no change in anatomical characteristics was observed. The changing EndoAnchor implant was positioned in an area with a high calcium load. In the other patient, 10 EndoAnchor implants were also deployed (4 with good deployment, 1 borderline, and 4 nonpenetrating on the first scan). There was a type Ia endoleak visible on the first CTA; however, it resolved after 38 months. At the location of 1 EndoAnchor implant there was a slight

**Table 2.** Characteristics of the Aorta, Endograft, and EndoAnchor Implants in a Case Where 1 EndoAnchor Became Borderline Penetrating and 1 Nonpenetrating.<sup>a</sup>

Characteristics		
Follow-up, mo	11	
Endograft	32-mm Zenith	
Oversizing, % (at baseline)	23.4	
Number of EndoAnchors	4	
	30-day CT	11-month CT
Good penetration	2	0
Borderline penetration	0	1
No penetration	2	3
Endoleak	Yes	Yes
Measurements		
Suprarenal aortic diameter, mm	26.3	25.2
Aortic diameter		
at lowest renal artery, mm	24.5	27
5 mm below lowest renal artery, mm	28.3	32.1
10 mm below lowest renal artery, mm	30.9	35.2
Proximal neck length, mm	3.2	2.6
Maximum sac diameter, mm	51.5	48.5
Suprarenal angulation, deg	10	5
Infrarenal angulation, deg	9	6
Infrarenal angulation to bifurcation, deg	16	29
Neck thrombus average thickness, mm	0	1.5
Neck thrombus circumference, deg	0	29
Neck calcium average thickness, mm	0	0
Neck calcium circumference, deg	0	0

Abbreviation: CT, computed tomography.

<sup>a</sup>See Figure 2.

increase in aortic diameter (2 mm), causing the implant to change position (borderline). Figure 4 shows the distribution of the 5 EndoAnchors that shifted position on the axial view of the aortic circumference from the CLL reconstruction.

### Angle Measurements

The median orthogonal angles of the EndoAnchor implants with good penetration on the first and last CTA scans were 92° (IQR 85, 98) and 90° (IQR 84, 97), respectively ( $p=0.822$ ). For the longitudinal angles the medians were 85° (IQR 71, 96) and 84° (IQR 70, 96), respectively ( $p=0.043$ ). This resulted in a median difference of 1.0° (IQR -7.0, 7.0) for the orthogonal angles and 2.0° (IQR -6.0, 9.0) for the

longitudinal angles between the first and last scans. Figure 5 shows scatterplots of the differences between the angle measurements.

### Endoleak Analysis

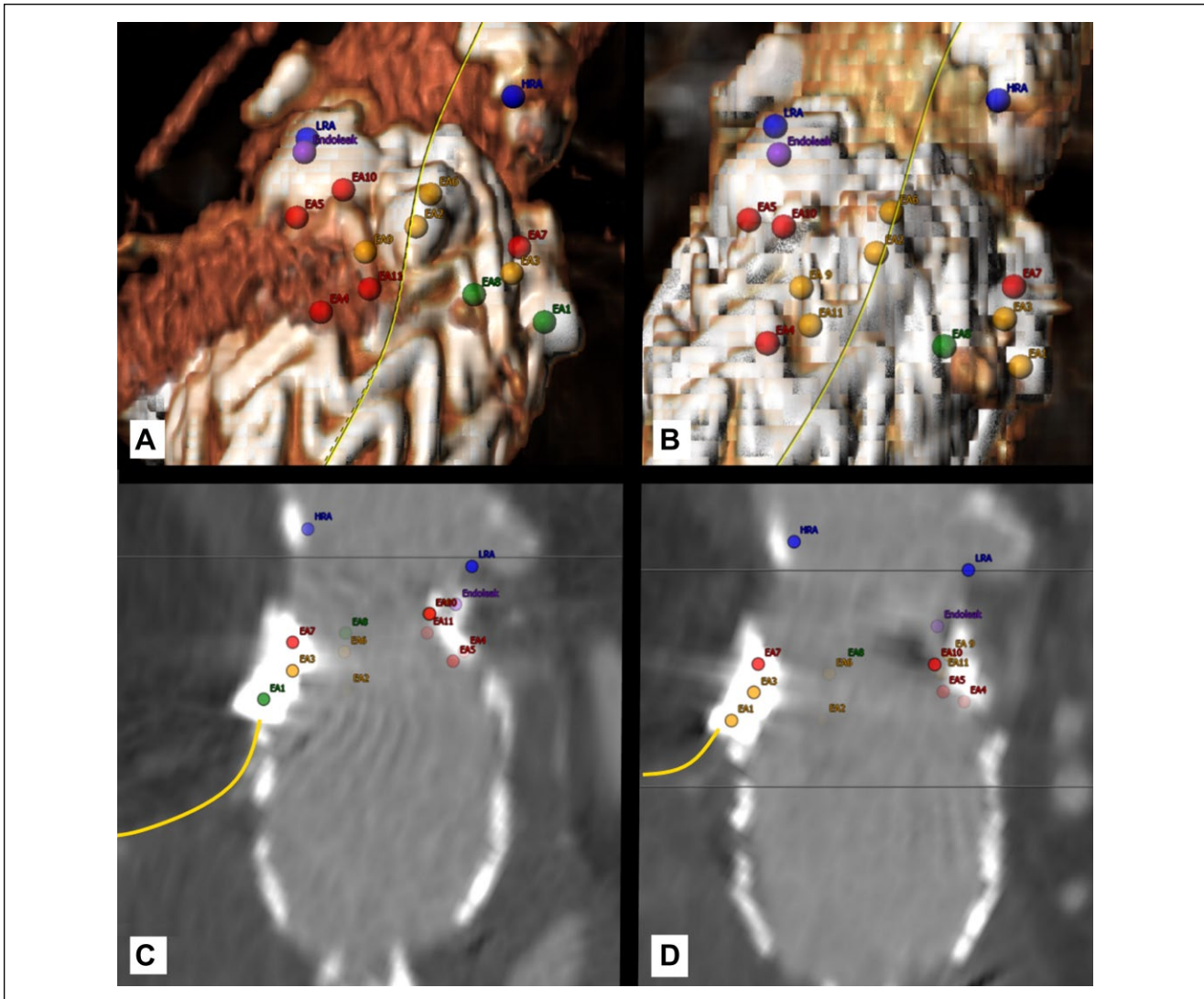
Thirty-six (67%) patients had no type Ia endoleak on both the first and last postprocedure CT scans. Of 18 (33%) patients who had a type Ia endoleak on the first CT scan, 6 resolved over time (without additional treatment). The median time interval between the first and last CTA scan of the 12 patients who had a persistent endoleak was 8.5 months (IQR 3, 13) vs 32 months (IQR 30, 36) for the 6 patients with a resolved endoleak. The median number of implanted EndoAnchors was 7 (IQR 4, 9) for the persistent endoleak subgroup vs 10 (IQR 5, 10) for the resolved endoleak subgroup.

Of the 12 persistent type Ia endoleaks, one was treated with coil embolization of the aneurysm 6 months after placement of the EndoAnchors. In 1 patient the intraoperative type Ia endoleak was resolved after deployment of an additional 5 EndoAnchors 23.5 months after the initial procedure. Another patient had 10 EndoAnchor implants deployed at 12.7 months after the initial procedure, however, without success; a conversion to open repair was performed at 25.6 months. In 1 patient an aortic extender cuff with additional EndoAnchor implants were deployed at 2.1 months after the initial procedure (only EndoAnchors before the cuff placement were analyzed). In 8 patients no reinterventions were performed to resolve the persistent type Ia endoleak.

### Discussion

In this initial analysis of the change in penetration depth and angle of EndoAnchors over time, nearly all EndoAnchors maintained good penetration over a >1-year period. Only when a gap occurred between the fabric and the aortic wall above the location of an EndoAnchor would an implant be at risk of changing position, as illustrated in Figure 6. In the few cases in which this occurred, the change in penetration did not produce clinical sequelae. Because of the rarity of EndoAnchor position changes, no conclusions can be drawn regarding any association between failure and their location on the aortic circumference. Reasons for initial borderline and nonpenetrating EndoAnchor implants were previously investigated<sup>11</sup> and not the aim of the current study.

The percentage of type Ia endoleaks in this cohort is higher compared to previous 1-year results from the ANCHOR registry<sup>4</sup> (33% vs 7%, respectively). The most important reason is the fact that this sample was a subcohort from the ANCHOR registry and included only patients treated for a type Ia endoleak without any other adjuncts (ie, cuffs or chimney extensions).



**Figure 3.** (A, B) Three-dimensional and (C, D) longitudinal views of the distribution of EndoAnchor implants at the (A, C) 30-day and the (B, D) 34-month computed tomography angiography scans. Good, borderline, and nonpenetrating EndoAnchor implants are visualized as green, orange, and red dots, respectively. The orange line accentuates the location of the aneurysm sac. The location of the endoleak is visualized with a purple dot. The blue dots represent the locations of the highest and lowest renal arteries (HRA and LRA, respectively). Note that only 2 EndoAnchors had good penetration during initial implant. The majority of EndoAnchors were applied beyond the recommended use.

Despite the presence of a type Ia endoleak in 18 patients, the mean aneurysm diameter decreased significantly, which is in line with findings from a matched cohort comparison of patients with and without EndoAnchor implants.<sup>12</sup> This observation might be due to the ability of well-secured EndoAnchors to resist the pressure of the endoleak between the aortic wall and endograft.

If a persistent type Ia endoleak is associated with sac growth during follow-up, the previous use of EndoAnchors does not preclude renewed endovascular interventions. The only drawback may occur with a borderline penetrating EndoAnchor in the proximal seal zone; here, the intraluminal

ends of the implant in the space between the endograft fabric and aortic wall can cause gutters that are hard to resolve. In these cases, a more proximal seal zone must be created using chimney or fenestrated cuffs, or the endograft should be explanted.

This subcohort showed a 48% maldeployment rate among the initially deployed EndoAnchors compared to 29% in a previous study limited to the 1-month CTA scans.<sup>11</sup> The most common reason for maldeployment was the presence of substantial gaps (>2 mm) between the endograft and aortic wall due to thrombus or owing to the position of the EndoAnchor below the aortic neck, which is defined as

**Table 3.** Characteristics of the Aorta, Endograft, and EndoAnchor Implants in a Case Where 1 EndoAnchor Became Borderline Penetrating.<sup>a</sup>

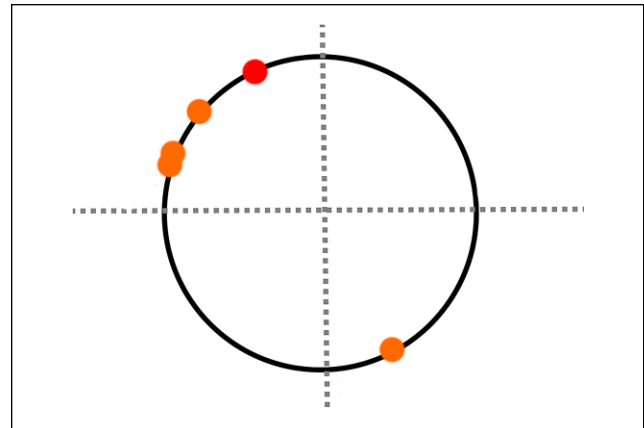
Characteristics		
Follow-up, mo	34	
Endograft	28.5-mm Excluder	
Oversizing, % (at baseline)	12.4%	
Number of EndoAnchors	11	
	30-day CT	34-month CT
Good penetration	2	1
Borderline penetration	4	5
No penetration	5	5
Endoleak	Yes	Yes
Measurements		
Suprarenal aortic diameter, mm	27.1	26.0
Aortic diameter		
at lowest renal artery, mm	24.9	24.8
5 mm below lowest renal artery, mm	25.9	25.4
10 mm below lowest renal artery, mm	31.0	28.5
Proximal neck length, mm	6.5	8.0
Maximum sac diameter, mm	90.6	85.6
Suprarenal angulation, deg	16	11
Infrarenal angulation, deg	12	18
Infrarenal angulation to bifurcation, deg	12	18
Neck thrombus average thickness, mm	0	0
Neck thrombus circumference, deg	0	0
Neck calcium average thickness, mm	0	2
Neck calcium circumference, deg	54	54

Abbreviation: CT, computed tomography.

<sup>a</sup>See Figure 3.

EndoAnchor application beyond the recommended use. In this analysis, relatively more EndoAnchors were deployed beyond the recommended use; however, this study also showed that complete penetration of all the implanted EndoAnchors is not required for clinical success.

There was a significant difference between the longitudinal angles on the first and last postprocedure scans. A possible explanation may be the large deviation among all measured EndoAnchors. Moreover, the aorta is a dynamic environment and the orientation of the EndoAnchors might change during the cardiac cycle as longitudinal forces on the endograft and the EndoAnchors fluctuate during this cycle. The CT scans were static images, and no dynamic imaging



**Figure 4.** The distribution of 5 EndoAnchors that became borderline or nonpenetrating (orange and red dots, respectively) is shown on the axial view of the aortic circumference from the center lumen line reconstruction.

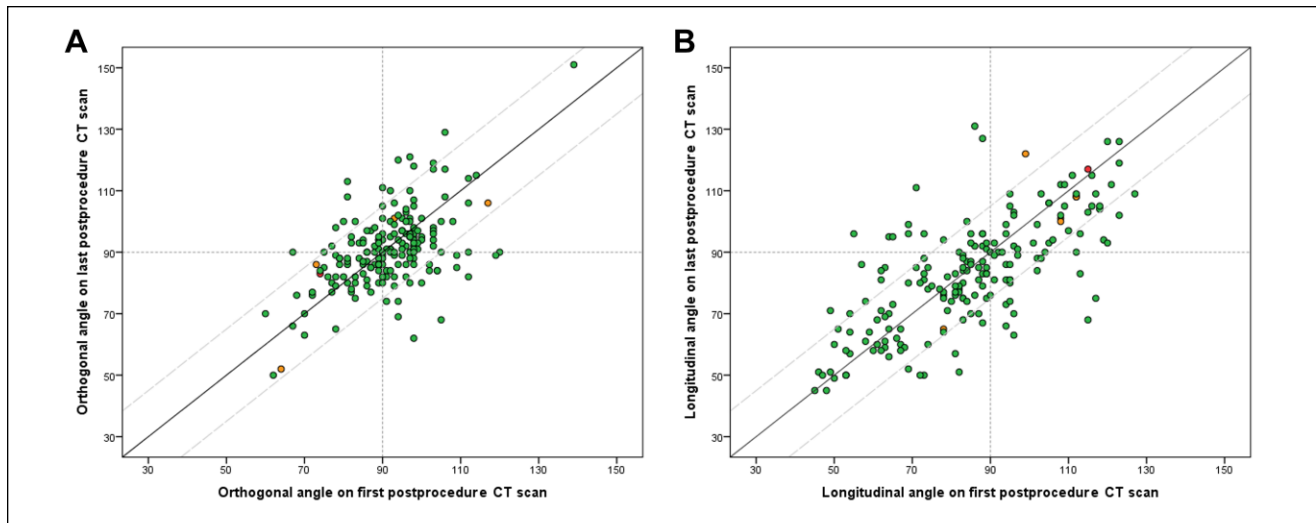
was performed to assess the differences in penetration angles. Due to this uncertainty in measurements, a small change in EndoAnchor penetration angle ( $\pm 15^\circ$ ) did not have any clinical consequences in the current cohort, which substantiates our previous study on EndoAnchor penetration angles.<sup>11</sup> No crosschecking in angle measurements could be performed with other imaging modalities such as radiographs or electrocardiographically-gated CTA; therefore, no assumption can be made about the deviation of angles.

If an EndoAnchor implant is positioned according to the recommended use and no forces are applied on the EndoAnchor between the aortic wall and endograft after deployment, the implant will be unlikely to change position over time. Therefore, it is important to have good initial penetration of the EndoAnchor. To do so, pre- and periprocedural planning and techniques need to be carefully executed.<sup>6</sup>

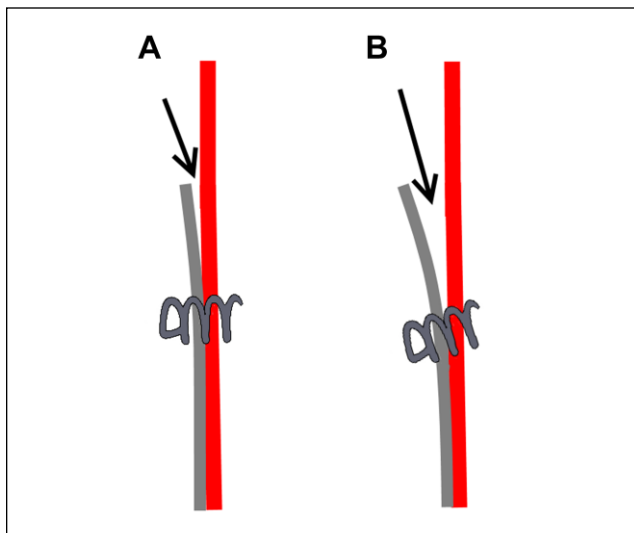
First, preplanning of the procedure is important. The aortic neck needs to be inside the recommended instructions for use for optimal positioning. Moreover, oversizing of the endograft needs to be between the 15% and 20% in order to have good apposition of the endograft, without the risk of infolding. Excessive oversizing creates fabric rucking, which may contribute to inadequate deployment due to increased fabric thickness and increased gaps between fabric and aortic wall.

Second, to ensure technical success in positioning the implants, the radius of the endoguide needs to match the diameter of the aortic neck, and the position of the C-arm relative to the endoguide and EndoAnchors needs to be perfectly perpendicular to visualize the proper penetration angles.

During the initial insertion of an EndoAnchor into the aortic wall, the physician may sense an increased



**Figure 5.** Scatterplots of the (A) orthogonal and (B) longitudinal angles at the first vs the last postprocedure computed tomography angiography (CTA) scan. The reference line (bold black line) shows the EndoAnchors for which the orthogonal angle remains the same on sequential CTA scans. The 2 dashed gray lines delineate the EndoAnchors for which the difference between measured orthogonal angles was  $<15^\circ$ . The 183 EndoAnchor implants that have good penetration are visualized in green. The EndoAnchor implants that turned borderline ( $n=4$ ) and nonpenetrating ( $n=1$ ) are visualized in orange and red, respectively.



**Figure 6.** Longitudinal schematic representation of (A) an EndoAnchor penetrating the aortic wall (red line); however, there is a space between the aortic wall and the endograft (gray line) proximal to the EndoAnchor implant. (B) Over time, the gap at the proximal edge of the endograft increases due to the pressurization of the gap, which may cause the EndoAnchor to become borderline or even nonpenetrating.

resistance of the Heli-FX endosystem. If this occurs, it is strongly advised to reload the EndoAnchor into the applicator and find another location on the aortic wall. During implantation, the tip of the endoguide and applicator should

be perpendicular to the endograft fabric. The more the EndoAnchor is deployed off this axis, the higher its risk of failing to penetrate the aortic wall. This can be observed on the angiogram, and physicians need to consider implanting an extra EndoAnchor.

### Limitations

This study included a small cohort of patients with only 13-month follow-up. As European guidelines suggest, 1-year follow-up is performed with CT followed by yearly duplex scans. Therefore, a great number of patients do not have more than the 1-year CT follow-up. No dynamic CTA scans were available; only static CTA scans were used. Therefore, changes in EndoAnchor implant penetration and angles during the cardiac cycle were not measured, though it might be interesting to investigate the imaging of EndoAnchors during the cardiac cycle.

This study did not incorporate measurements of the aortic wall thickness on the preprocedural CT scans in relation to the 2-mm EndoAnchor penetration depth. Because of metal artifacts in the endograft and EndoAnchors and the calcium in the aortic wall, accurate measurements of the aortic wall thickness post-EVAR would be rather imprecise. Moreover, the aortic wall may also be slightly compressed due to oversizing and the radial force of the endograft. Planning aspects and reports were not available, though preplanning would not be done for EndoAnchor use to treat intraoperative type Ia endoleaks.



## Conclusion

Despite the small number of EndoAnchors analyzed, this study showed that the sustainability of EndoAnchors with initially good penetration is very satisfactory at 1-year follow-up. Borderline or nonpenetrating EndoAnchors were rare and were not associated with any clinical consequences. This analysis emphasizes the utmost importance of delivering EndoAnchor implants accurately and effectively through the aortic wall.


## Declaration of Conflicting Interests


The author(s) declared the following potential conflicts of interest with respect to the research, authorship, and/or publication of this article: William D. Jordan Jr, Jean M. Panneton, and Jean-Paul P.M. de Vries are consultants and on the Scientific Advisory Board for Medtronic, Inc.

## Funding

The author(s) disclosed receipt of the following financial support for the research, authorship, and/or publication of this article: This research was supported by a restricted grant from Medtronic, Inc.

## ORCID iDs

Kim van Noort  <https://orcid.org/0000-0002-7181-8999>

Seline R. Goudekettering  <https://orcid.org/0000-0003-2565-7482>

## References

1. Avci M, Vos JA, Kolvenbach RR, et al. The use of EndoAnchors in repair EVAR cases to improve proximal endograft fixation. *J Cardiovasc Surg (Torino)*. 2012;53:419–426.
2. Vries de JPPM, Pavoordt van de HDWM, Jordan WD Jr. Rationale of EndoAnchors in abdominal aortic aneurysms with short or angulated necks. *J Cardiovasc Surg (Torino)*. 2014;55:103–107.
3. De Vries JPPM, Ouriel K, Mehta M, et al. Analysis of EndoAnchors for endovascular aneurysm repair by indications for use. *J Vasc Surg*. 2014;60:1460–1467.
4. Jordan WD Jr, Mehta M, Ouriel K, et al. One-year results of the ANCHOR trial of EndoAnchors for the prevention and treatment of aortic neck complications after endovascular aneurysm repair. *Vascular*. 2016;24:177–186.
5. Jordan WD Jr, de Vries JP, Ouriel K, et al. Midterm outcome of EndoAnchors for the prevention of endoleak and stent-graft migration in patients with challenging proximal aortic neck anatomy. *J Endovasc Ther*. 2015;22:163–170.
6. de Vries JPPM, Jordan WD Jr. Improved fixation of abdominal and thoracic endografts with use of Endoanchors to overcome sealing issues. *Gefässchirurgie*. 2014;19:212–219.
7. Melas N, Perdikides T, Saratzis A, et al. Helical EndoStaples enhance endograft fixation in an experimental model using human cadaveric aortas. *J Vasc Surg*. 2012;55:1726–1733.
8. Goudekettering SR, Wille J, van den Heuvel DAF, et al. Midterm single-center results of endovascular aneurysm repair with additional EndoAnchors. *J Endovasc Ther*. 2019;26:90–100.
9. Tassiopoulos AK, Monastiriotis S, Jordan WD, et al. Predictors of early neck dilatation after endovascular aneurysm repair with EndoAnchors. *J Vasc Surg*. 2017;66:45–52.
10. Goudekettering SR, van Noort K, Ouriel K, et al. Influence of aortic neck characteristics on successful aortic wall penetration of EndoAnchors in therapeutic use during endovascular aneurysm repair. *J Vasc Surg*. 2018; 68:1007–1016.
11. Goudekettering SR, van Noort K, Vermeulen JJM, et al. Analysis of the position of EndoAnchors in therapeutic use during endovascular aneurysm repair [published online December 19, 2018]. *J Vasc Surg*. doi:10.1016/j.jvs.2018.09.035
12. Muhs BE, Jordan W, Ouriel K, et al. Matched cohort comparison of endovascular abdominal aortic aneurysm repair with and without EndoAnchors. *J Vasc Surg*. 2018;67:1699–1707.