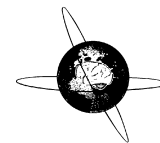




Contents lists available at [ScienceDirect](#)

## Clinical Neurophysiology Practice

journal homepage: [www.elsevier.com/locate/cnp](http://www.elsevier.com/locate/cnp)



### Corrigendum

Corrigendum to “A revised glossary of terms most commonly used by clinical electroencephalographers and updated proposal for the report format of the EEG findings. Revision 2017” [Clin. Neurophysiol. Practice 2 (2017) 170–185]



Nick Kane<sup>a,\*</sup>, Jayant Acharya<sup>b</sup>, Sandor Beniczky<sup>c</sup>, Luis Caboclo<sup>d</sup>, Simon Finnigan<sup>e</sup>, Peter W. Kaplan<sup>b</sup>, Hiroshi Shibasaki<sup>f</sup>, Ronit Pressler<sup>a</sup>, Michel J.A.M. van Putten<sup>g</sup>

<sup>a</sup> UK

<sup>b</sup> USA

<sup>c</sup> Denmark

<sup>d</sup> Brazil

<sup>e</sup> Australia

<sup>f</sup> Japan

<sup>g</sup> Netherlands

The authors regret

Beta band: Frequency band of >13–30 Hz inclusive. Greek letter:  $\beta$ .

Beta rhythm or activity: Any EEG rhythm between >13 and 30 Hz (wave duration >33–76 ms).

The authors would like to apologise for any inconvenience caused.

DOI of original article: <https://doi.org/10.1016/j.cnp.2017.07.002>

\* Corresponding author at: North Bristol NHS Trust, Grey Walter Department of Clinical Neurophysiology, Southmead Hospital, Bristol BS10 5NB, UK.  
E-mail address: [Nick.Kane@nbt.nhs.uk](mailto:Nick.Kane@nbt.nhs.uk) (N. Kane).

<https://doi.org/10.1016/j.cnp.2019.06.001>

2467-981X/© 2019 International Federation of Clinical Neurophysiology. Published by Elsevier B.V.

This is an open access article under the CC BY-NC-ND license (<http://creativecommons.org/licenses/by-nc-nd/4.0/>).