

Physiological Appearance of Hybrid FDG–Positron Emission Tomography/Computed Tomography Imaging Following Uncomplicated Endovascular Aneurysm Sealing Using the Nellix Endoprosthesis

Journal of Endovascular Therapy
 1–7

© The Author(s) 2020





Article reuse guidelines:

sagepub.com/journals-permissions

DOI: 10.1177/1526602820913888

www.jevt.org



Erik Groot Jebbink, PhD^{1,2}, Leo H. van den Ham, MD¹,
 Beau B. J. van Woudenberg, BSc¹, Riemer H. J. A. Slart, MD, PhD^{4,5},
 Clark J. Zeebregts, MD, PhD⁶, Ton J. M. Rijnders, MD³,
 Jan-Willem H. P. Lardenoije, MD, PhD¹, and Michel M. P. J. Reijnen, MD, PhD^{1,2}

Abstract

Purpose: To investigate the physiological uptake of hybrid fluorine-18-fluorodeoxyglucose (FDG)–positron emission tomography/computed tomography (PET/CT) before and after an uncomplicated endovascular aneurysm sealing (EVAS) procedure as a possible tool to diagnose EVAS graft infection and differentiate from postimplantation syndrome. **Materials and Methods:** Eight consecutive male patients (median age 78 years) scheduled for elective EVAS were included in the prospective study (*ClinicalTrials.gov* identifier NCT02349100). FDG-PET/CT scans were performed in all patients before the procedure and 6 weeks after EVAS. The abdominal aorta was analyzed in 4 regions: suprarenal, infrarenal neck, aneurysm sac, and iliac. The following parameters were obtained for each region: standard uptake value (SUV), tissue to background ratio (TBR), and visual examination of FDG uptake to ascertain its distribution. Demographic data were obtained from medical files and scored based on reporting standards. **Results:** Visual examination showed no difference between pre- and postprocedure FDG uptake, which was homogenous. In the suprarenal region no significant pre- and postprocedure differences were observed for the SUV and TBR parameters. The infrarenal neck region showed a significant decrease in the SUV and no significant decrease in the TBR. The aneurysm sac and iliac regions both showed a significant decrease in SUV and TBR between the pre- and postprocedure scans. **Conclusion:** Physiological FDG uptake after EVAS was stable or decreased with regard to the preprocedure measurements. Future research is needed to assess the applicability and cutoff values of FDG-PET/CT scanning to detect endograft infection after EVAS.

Keywords

aortic aneurysm, endovascular aneurysm sealing, fluorine-18-fluorodeoxyglucose, graft infection, positron emission tomography / computed tomography

Introduction

Endovascular aneurysm repair (EVAR) has become the standard of care for the treatment of infrarenal abdominal aortic aneurysms (AAA). Despite numerous advances in EVAR devices, the need for secondary interventions to treat complications such as endoleaks and migration remains an issue.^{1,2} One of the latest innovations is endovascular aneurysm sealing (EVAS), a technique based on polymer filling of endobags surrounding dual stent frames that aimed to prevent endoleaks of any type.³ Early results were promising, but the applicability was reduced significantly by a refinement of the instructions for use (IFU), driven by the incidence of late failures.^{3,4}

Like EVAR, a prosthetic graft infection may also occur after EVAS. Prosthetic graft infection, with an incidence

¹Department of Surgery, Rijnstate Hospital, Arnhem, the Netherlands

²Multi-Modality Medical Imaging Group, Technical Medical Centre, University of Twente, Enschede, the Netherlands

³Department of Nuclear Medicine, Rijnstate Hospital, Arnhem, the Netherlands

⁴Department of Nuclear Medicine and Molecular Imaging, Medical Imaging Center, University Medical Center Groningen, University of Groningen, the Netherlands

⁵Biomedical Photonic Imaging Group, University of Twente, Enschede, the Netherlands

⁶Department of Surgery, Division Vascular Surgery, University Medical Center Groningen, University of Groningen, the Netherlands

Corresponding Author:

Erik Groot Jebbink, Department of Surgery, Rijnstate Hospital, Wagnerlaan 55, 6815 AD Arnhem, the Netherlands.

Email: erik.grootjebbink@gmail.com

ranging from 0.16% to 0.77%, is a life-threatening complication with a mortality rate of 18% to 50%.⁵⁻⁷ Diagnosing vascular prosthetic graft infection is a challenge as clinical signs vary greatly and are often nonspecific.⁸ In the early phase after implantation, the postimplantation syndrome (PIS) might interfere with the diagnosis of a true infection.⁹

Hybrid fluorine-18-fluorodeoxyglucose (FDG) positron emission tomography (PET) combined with computed tomography (FDG-PET/CT) is frequently used as the preferred diagnostic tool for graft infection.^{3,10} Visual examination, the standard uptake value (SUV), and the tissue to background ratio (TBR) are parameters that reflect the intensity of FDG uptake. A linear, diffuse, and homogeneous uptake is not indicative of an infection, whereas focal or heterogeneous uptake with a projection matching the vessel on CT is highly suggestive.¹¹ In addition to infection, a (moderately) increased FDG uptake is also associated with scar tissue, native vessels, and postsurgical inflammatory changes.¹² A chronic aseptic inflammation due to the synthetic graft material mediated primarily by fibroblasts, foreign-body giant cells, and macrophages may also cause a potential base for some FDG uptake.^{13,14} False-positive FDG-PET/CT imaging may result in a diagnostic error and antibiotic overuse, particularly in the first 6 to 8 weeks after surgery.¹⁵

Little is known about the physiological FDG uptake after EVAR. A recent publication by Marie et al¹⁶ showed no increased FDG uptake 1 month after EVAR compared with the preprocedure FDG uptake. However, after 6-month follow-up a significant increase in FDG uptake was observed, which was related to patients with minimal AAA shrinkage.

So far, no study has provided information on the physiological FDG uptake after EVAS. This is important to assess the applicability of FDG-PET/CT scanning for the detection of an (early) endograft infection. Therefore, a study was undertaken to examine the physiological effect of EVAS on the FDG uptake in the vascular wall in patients who underwent an uncomplicated EVAS procedure.

Materials and Methods

Study Design

This prospective, within-subject, exploratory study evaluated patients scheduled for elective AAA treatment using the Nellix endoprosthesis (Endologix, Irvine, CA, USA) between January 2015 and January 2017. Patients were ineligible for the study if they had diabetes, known inflammatory disease, or malignancy. Medical files of the included patients were screened for demographic data and scored according to the reporting standards.¹⁷

This study was conducted in accordance with the principles of the Declaration of Helsinki and Good Clinical

Practice guidelines. The study was approved by the medical ethics committee of the region Arnhem-Nijmegen (NL50251.091.14) and the local institutional review board. All participants in the study gave informed consent. The trial was registered on the National Institutes of Health website (*ClinicalTrials.gov*; identifier NCT02349100).

EVAS Technique. The procedures were performed according to the manufacturer's IFU and under antibiotic prophylaxis, as previously described.¹⁸ Briefly, after gaining access to the femoral arteries, angiography with a calibrated catheter was performed to establish the specific device length needed. After positioning the devices so that the endobags were below the most caudal renal artery, the outer sheaths were retracted. The endobags are evacuated, and the stent balloons were simultaneously inflated to deploy the stents. A prefill of the endobags was performed with nonheparinized saline under pressure monitoring to assess the volume of polymer required to exclude the aneurysm. After emptying the endobags, the polymer was injected at a target pressure of 180 mm Hg. During polymer curing the balloons were reinflated. After polymer filling, final angiography was performed to confirm the complete seal of the aneurysm sac and absence of endoleaks.

Scanning Protocol. FDG-PET/CT scans (Philips Gemini TF64; Philips Medical Systems, Best, the Netherlands) were performed in all patients before and 6 weeks after treatment. FDG (Cyclotron BV, Amsterdam, the Netherlands) was used as a tracer for detection of inflammatory activity. Patients had to fast for 6 hours prior to scanning and drink 1 L of water 2 hours prior to scanning. One hour prior to scanning the FDG was administered intravenously, and the patients rested for 30 minutes. The administered amount of FDG (Mq) was based on patient body weight (bw) [(3.125/kg bw) * 1.17 MBq]. Data concerning body mass index (BMI), glucose levels, and FDG doses and scanning time were recorded for each scan.

IDS7 (version 19.1; Sectra, Linköping, Sweden) was used to analyze the FDG-PET/CT scans. Regions of interest (ROI) were drawn using a free hand tool. The SUV_{max}, defined as the SUV of the voxel with the highest SUV within a selected ROI, was used for semiquantitative analysis of the FDG-PET/CT data. The program automatically corrected for BMI and the time of injection. Correction for glucose was performed manually using a correction factor [glucose level (mmol/L) / 5 (mmol/L) * SUV]. Furthermore, TBR, which represents the SUV corrected for background noise, was calculated by dividing the SUV_{max} by the SUV_{max} of the ascending aorta blood pool lumen. The slice where the ascending aorta was observed as a round structure was used for calculations. The abdominal aorta was divided in 4 subregions as

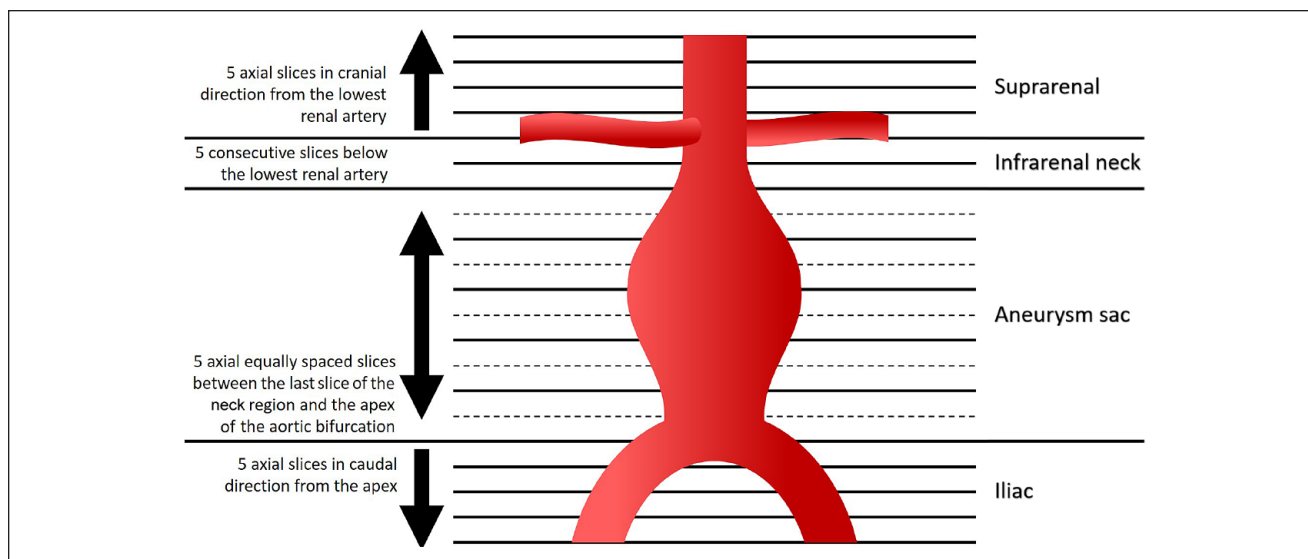


Figure 1. Overview of measurement regions. The arrows indicate the direction of measurement.

depicted in Figure 1. Five consecutive slices were selected in the cranial direction for the suprarenal region and another 5 consecutive slices below the lowest renal artery for the infrarenal neck region. The aneurysm sac region was defined over 5 equally spaced slices between the last slice of the infrarenal neck region and the apex of the aortic bifurcation. The iliac region consisted of 5 consecutive slices selected caudal of the apex of the aortic bifurcation. In every slice, the SUVmax was determined in a manually selected ROI (Figure 2) around the edges of the activity of the vascular wall. Thrombus and/or calcification were included in the ROI.

Besides determination of the SUV and TBR, visual assessment was performed by a nuclear medicine physician (RS). The FDG-PET/CT scans were assessed on heterogeneity and intensity of FDG uptake, which was graded on a 4-point scale.¹¹ Grade 1 is an FDG uptake similar to that in the background. Grade 2 implies low FDG uptake and is comparable with the FDG uptake by inactive muscles and fat. Grade 3 reflects moderate FDG uptake, clearly visible and higher than the uptake by inactive muscles and fat but distinctly less than the physiological urinary uptake by the bladder. Grade 4 means a strong FDG uptake, comparable to the physiological uptake by the bladder. The assessment of heterogeneity was classified as homogeneous, slightly heterogeneous, or heterogeneous.

Statistical Analysis

Data are reported as the median and interquartile range (IQR; Q1, Q3). Significant differences between the pre and post SUV and TBR were analyzed using the Wilcoxon test because of the small sample size and expected nonnormal

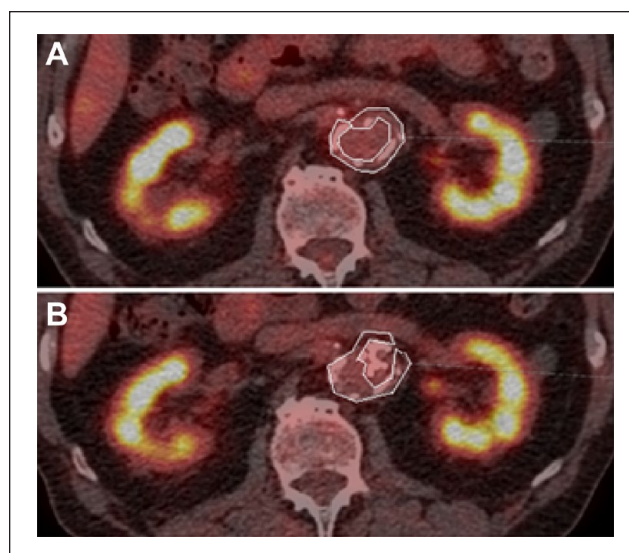


Figure 2. FDG-PET/CT fused-image axial slice of the abdomen including the region of interest (white lines) on the first slice of the infrarenal neck region showing infrarenal anatomy (A) before and (B) after endovascular aneurysm sealing; CT, computed tomography; FDG, fluorine-18-fluorodeoxyglucose; PET, positron emission tomography.

distribution of the data. Wilcoxon tests were also employed to assess whether the nonnormally distributed visual examinations were significantly different between the pre- to postprocedure examinations. Descriptive statistics were given for all values and measurements. Differences were considered significant at the $p < 0.05$ level. Data were analyzed using SPSS software (version 25; IBM Corporation, Armonk, NY, USA).

Table 1. Characteristics of the 8 Patients.^a

Age, y	78 (71, 80)
Men	8
Body mass index, kg/m ²	30.0 (28.3, 32.6)
ASA classification	
II	3
III	5
Comorbidities	
Smoking	4
Diabetes mellitus	0
Hypertension	5
Hyperlipidemia	3
Cardiac disease	4
Renal disease	5
PAD	3
Pulmonary disease	2
Family history AAA	0

Abbreviations: AAA, abdominal aortic aneurysm; ASA, American Society of Anesthesiologists; PAD, peripheral artery disease.

^aContinuous data are presented as the median (interquartile range Q1, Q3); categorical data are given as the number.

Table 2. FDG-PET/CT Scanning Parameters.^a

	Preprocedure	Postprocedure
Glucose, mmol/L	5.5 (5.3, 6.6)	5.4 (5.2, 6.6)
FDG, MBq	251.0 (237, 267)	263 (234, 280)

Abbreviations: FDG, fluorine-18-fluorodeoxyglucose; PET/CT, positron emission tomography/computed tomography.

^aData are presented as the median (interquartile range Q1, Q3).

Results

Of 11 patients recruited for the study, 8 male patients (median age 78 years) were analyzed after exclusion of 3 unevaluable cases. Two patients were excluded because a malignancy was detected on the preprocedure FDG-PET/CT; the third was converted to open repair during surgery due to occlusion of the left renal artery by a bulging left endobag after secondary fill. The baseline patient characteristics are given in Table 1, parameters of the FDG-PET/CT scans are summarized in Table 2, and operative details are given in Table 3.

Visual examination of the FDG-PET/CT scans showed no significant differences between the pre- and postprocedure studies (Table 4). All but 1 patient showed homogenous uptake, comparable to the background signal. Slightly heterogeneous but low uptake was observed in 1 patient due to increased uptake in the prostate and left abdomen.

SUV and TBR outcomes per region are displayed in Table 5. In the suprarenal region there were no significant differences between pre- and postprocedure SUVmax and TBR. For the infrarenal neck region, TBR did not decrease significantly between pre- and postprocedure scans. For the

Table 3. Procedure Details.^a

General anesthesia	8
Bilateral cutdown	8
Procedure time, min	76 (69.8, 95)
Blood loss, mL	100 (75, 425)
Prefill volume, mL	108 (97.3, 133)
Prefill pressure, mm Hg	180 (180, 180)
Polymer volume, mL	107 (96.3, 133)
Filling pressure, mm Hg	185 (180, 197.5)
Secondary fill volume, mL	5 (3.5, 8.5)
Technical success	8
Hospital stay, d	3 (3, 4)

^aContinuous data are presented as the median (interquartile range Q1, Q3); categorical data are given as the number.

aneurysm sac and iliac regions, all obtained measures decreased significantly between the pre- and postprocedure scans.

Endobag migration of 30 mm was observed in 1 patient after 48 months, leading to a type Is2 endoleak (categorized according to the work of van den Ham et al¹⁹) and 7-mm sac enlargement. The SUVmax in the suprarenal region increased for this patient from 2.1 to 2.4 between the pre- and postprocedure FDG-PET/CT scans. All the SUVmax in the other regions remained unchanged or decreased. The patient refrained from further treatment. One other patient showed 8-mm device migration, a type Is2 endoleak, and sac growth of 4 mm after 24 months. At 30 months, the Nellix graft was explanted and replaced by an aortobifemoral graft. No increase in SUVmax was observed for this patient.

Discussion

The present study has shown that FDG uptake after EVAS is significantly lower in the infrarenal and iliac segments compared to the preprocedure FDG uptake. This indicates that there is no increase in physiological inflammatory response of the aneurysm wall following EVAS. The preprocedure SUVmax results from our cohort were in range with those published for untreated AAAs and showed a homogenous uptake.²⁰ Furthermore, these SUVmax results were higher compared to those obtained in nonaneurysmal aortas, indicating the presence of an inflammatory process.²⁰ Last, the homogenous uptake on postprocedure visual inspection were in line with previously published SUVmax data from Keidar and Nitecki.¹²

In general, the literature suggests a cutoff value for the SUVmax of 8 in the perigraft area to distinguish infected grafts from noninfected grafts.^{11,21} The SUVmax results in the current study were all far below this cutoff value. Tolenaar et al²² presented 2 cases of endograft infection after EVAS that both showed high focal uptake (SUV 7.2

Table 4. Visual Assessment.

Patient No.	Grade ^a		Uptake Pattern	
	Pre	Post	Pre	Post
1	1	1	Homogenous	Homogenous
2	1	1	Homogenous	Homogenous
3	2	2	Slightly heterogeneous	Slightly heterogeneous
4	1	1	Homogenous	Homogenous
5	1	1	Homogenous	Homogenous
6	1	1	Homogenous	Homogenous
7	1	1	Homogenous	Homogenous
8	1	1	Homogenous	Homogenous

^aGrade 1, an FDG (fluorine-18-fluorodeoxyglucose) uptake similar to that in the background; grade 2, low FDG uptake and is comparable with the FDG uptake by inactive muscles and fat; grade 3, moderate FDG uptake, clearly visible and higher than the uptake by inactive muscles and fat but distinctly less than the physiological uptake by the bladder; grade 4, a strong FDG uptake comparable to the physiological uptake by the bladder.

Table 5. Standard Uptake Value (SUV) and Tissue to Background Ratio (TBR) per Region.^a

Parameter	Preprocedure	Postprocedure	p
Suprarenal			
SUVmax	2.5 (2.1, 3.4)	2.5 (2.3, 3.1)	0.4
TBR	0.9 (0.9, 1.0)	0.9 (0.9, 1)	0.5
Infrarenal neck			
SUVmax	2.8 (2.5, 3.2)	2.6 (2.2, 2.9)	0.036
TBR	1.0 (0.9, 1.1)	1.0 (0.8, 1.0)	0.6
Aneurysm sac			
SUVmax	2.6 (2.4, 3.6)	2.0 (1.9, 3.0)	0.012
TBR	1.0 (0.8, 1.1)	0.8 (0.8, 0.9)	0.017
Iliac			
SUVmax	2.8 (2.3, 3.8)	2.3 (2.1, 3.2)	0.012
TBR	1.0 (0.9, 1.0)	0.9 (0.8, 1.0)	0.036
Mean of regions			
SUVmax	2.6 (2.3, 3.5)	2.2 (2.1, 3.0)	0.017
TBR	1.0 (0.9, 1.0)	0.9 (0.9, 0.9)	0.069

^aData are presented as the median (interquartile range Q1, Q3).

and SUV 9.7) in the infected area. The results of Tolenaar et al²² may justify the use of FDG-PET/CT as a diagnostic tool to identify infection after EVAS, particularly since the current study showed that the physiological uptake after EVAS is low. In addition, Zogala et al²³ published a sensitivity of 89% and a specificity of 100% based on SUVmax, TBR, and visual grading of FDG-PET/CT scans to diagnose stent-graft infection.

When analyzing the results per region, the suprarenal segment did not show a decrease in SUVmax in comparison to the infrarenal regions. The suprarenal region is not covered by the endobags; blood flow perturbations caused by the endobag plateau (creating a step in the aortic diameter) in this area could mediate inflammatory processes in the vessel wall and an increase in FDG uptake. An increased

FDG uptake during follow-up could also be related to PIS, something that can be difficult to distinguish from true infection. Berg et al²⁴ found that the incidence of PIS is significantly lower after EVAS compared with a polyester stent-graft in EVAR, with a lower body temperature and lower serum leukocyte and C-reactive protein levels.²⁴

Marie and colleagues¹⁶ recently reported no significant increase in FDG-PET/CT uptake between 3 months before EVAR and 4 weeks after treatment. The FDG-PET/CT uptake between 3 months pre-EVAR and 6 months thereafter significantly increased, both under the threshold for infection (SUVmax 2.2 vs 2.6, respectively). An explanation between the decreased uptake we observed and the steady uptake shown by Marie et al¹⁶ after 4 weeks could be related to the high percentage of endoleaks (43% at 4 weeks and 39% at 6 months) in the Marie cohort, maintaining inflammatory processes in the vessel wall because of contact with the circulation. Marie et al¹⁶ also reported 6-month data, but it is questionable if our short-term results can be extrapolated to the 6-month time point. Therefore, additional follow-up at 6 or 12 months would be of added value in future studies.

Along the same line, Courtois et al²⁵ recently presented results about the predictive value of FDG-PET/CT in the detection of complications after EVAR. Our study cohort had 2 patients with complications (migration leading to type Ia endoleak and sac enlargement in both cases at 24 and 48 months). The FDG-PET/CT data showed only a minor increase in activity for the suprarenal region in one of these patients between the pre- or postprocedure scan.

Limitations

Comparison of FDG-uptake values between studies should always be done with great care, as there may be differences in the PET/CT scanner performance and the acquisition and interpretation of the data, as was recognized by the EARL

standard.²⁶ Furthermore, several methods exist to standardize the FDG uptake, either using the ascending aorta or the mediastinum. This could induce differences in reported FDG uptake values. Our method consisted of sampling 4 areas of the infrarenal vasculature using 5 slices per area. Other authors report results using all slices available; however, our software tool did not allow easy inclusion of a volume including all slices. This could influence the average FDG uptake per area.

Also, in AAAs without thrombus formation, the blood lumen (with high activity) is often partly included when assessing FDG uptake in the vessel wall. The EVAS endobags (without any activity) are adjacent to the vessel wall, causing lower postprocedure SUVmax readings. Last, the current study did not include any patients with a graft infection, so no conclusions on the cutoff for graft infection after EVAS can be reported.

Conclusion

The current study shows there is no increase, but stable or decreased physiological FDG uptake after EVAS. Future research is needed to assess the applicability and cutoff values of FDG-PET/CT scanning to detect endograft infection after EVAS.

Declaration of Conflicting Interests

The author(s) declared the following potential conflicts of interest with respect to the research, authorship, and/or publication of this article: Michel M. P. J. Reijnen has received speaker honoraria from Endologix, Terumo Aortic, and Bently and research grants from Endologix Inc.

Funding

The author(s) disclosed receipt of the following financial support for the research, authorship, and/or publication of this article: This work was supported by an unrestricted research grant from Endologix, Inc.

ORCID iDs

Erik Groot Jebbink  <https://orcid.org/0000-0001-7041-8603>

Michel M. P. J. Reijnen  <https://orcid.org/0000-0002-5021-1768>

References

- Patel SR, Allen C, Grima MJ, et al. A systematic review of predictors of reintervention after EVAR: guidance for risk-stratified surveillance. *Vasc Endovasc Surg*. 2017;51:417–428.
- Paravastu SCV, Jayarajasingam R, Cottam R, et al. Endovascular repair of abdominal aortic aneurysm. *Cochrane Database Syst Rev*. 2014;(1):CD004178.
- Reijnen MMPJ, Holden A. Status of endovascular aneurysm sealing after 5 years of commercial use. *J Endovasc Ther*. 2018;25:201–206.
- Carpenter JP, Lane JS 3rd, Trani J, et al. Refinement of anatomic indications for the Nellix System for endovascular aneurysm sealing based on 2-year outcomes from the EVAS FORWARD IDE trial. *J Vasc Surg*. 2018;68:720–730.e1.
- Ducasse E, Calisti A, Speziale F, et al. Aortoiliac stent graft infection: current problems and management. *Ann Vasc Surg*. 2004;18:521–526.
- Cernohorsky P, Reijnen MMPJ, Tielliu IFJ, et al. The relevance of aortic endograft prosthetic infection. *J Vasc Surg*. 2011;54:327–333.
- Vogel TR, Symons R, Flum DR. The incidence and factors associated with graft infection after aortic aneurysm repair. *J Vasc Surg*. 2008;47:264–269.
- Bruggink JL, Slart RH, Pol JA, et al. Current role of imaging in diagnosing aortic graft infections. *Semin Vasc Surg*. 2011;24:182–190.
- Radak D, Djukic N, Tanaskovic S, et al. Should we be concerned about the inflammatory response to endovascular procedures? *Curr Vasc Pharmacol*. 2017;15:230–237.
- Keidar Z, Bar-Shalom R, Nitecki S, et al. Prosthetic vascular graft infection: the role of FDG-PET/CT. *J Nucl Med*. 2007;48(suppl 2):63P.
- Saleem BR, Pol RA, Slart RH, et al. 18F-Fluorodeoxyglucose positron emission tomography/CT scanning in diagnosing vascular prosthetic graft infection. *Biomed Res Int*. 2014;2014:471971.
- Keidar Z, Nitecki S. FDG-PET for the detection of infected vascular grafts. *Q J Nucl Med Mol Imaging*. 2009;53:35–40.
- Hagerty RD, Salzman DL, Kleinert LB, et al. Cellular proliferation and macrophage populations associated with implanted expanded polytetrafluoroethylene and polyethyleneterephthalate. *J Biomed Mater Res*. 2000;49:489–497.
- Salzman DL, Kleinert LB, Berman SS, et al. Inflammation and neovascularization associated with clinically used vascular prosthetic materials. *Cardiovasc Pathol*. 1999;8:63–71.
- Legout L, D'Elia P, Sarraz-Bournet B, et al. Diagnosis and management of prosthetic vascular graft infections. *Med Mal Infect*. 2012;42:102–109.
- Marie P-Y, Plissonnier D, Bravetti S, et al. Low baseline and subsequent higher aortic abdominal aneurysm FDG uptake are associated with poor sac shrinkage post endovascular repair. *Eur J Nucl Med Mol Imaging*. 2018;45:549–557.
- Stoner MC, Calligaro KD, Chaer RA, et al. Reporting standards of the Society for Vascular Surgery for endovascular treatment of chronic lower extremity peripheral artery disease. *J Vasc Surg*. 2016;64:e1–e21.
- van den Ham LH, Zeebregts CJ, de Vries J-PPM, et al. Abdominal aortic aneurysm repair using Nellix EndoVascular Aneurysm Sealing. *Surg Technol Int*. 2015;26:226–231.
- van den Ham LH, Holden A, Savlovskis J, et al. Editor's Choice. Occurrence and classification of proximal type I endoleaks after EndoVascular Aneurysm Sealing using the Nellix™ device. *Eur J Vasc Endovasc*. 2017;54:729–736.
- Truijers M, Kurvers HA, Bredie SJ, et al. In vivo imaging of abdominal aortic aneurysms: increased FDG uptake suggests inflammation in the aneurysm wall. *J Endovasc Ther*. 2008;15:462–467.

21. Tokuda Y, Oshima H, Araki Y, et al. Detection of thoracic aortic prosthetic graft infection with 18F-fluorodeoxyglucose positron emission tomography/computed tomography. *Eur J Cardiothorac Surg*. 2013;43:1183–1187.
22. Tolenaar JL, van den Ham LH, Reijnen MMPJ, et al. Late conversion after sac anchoring endoprosthesis for secondary aortic aneurysm infection. *J Endovasc Ther*. 2015;22:813–818.
23. Zogala D, Rucka D, Ptacnik V, et al. How to recognize stent graft infection after endovascular aortic repair: the utility of 18F-FDG PET/CT in an infrequent but serious clinical setting. *Ann Nucl Med*. 2019;33:594–605.
24. Berg P, Stroetges RA, Miller LE, et al. A propensity score-matched analysis of inflammatory response with endovascular aneurysm sealing vs endovascular aneurysm repair. *J Endovasc Ther*. 2017;24:670–674.
25. Courtois A, Makrygiannis G, El Hachemi M, et al. Positron emission tomography/computed tomography predicts and detects complications after endovascular repair of abdominal aortic aneurysms. *J Endovasc Ther*. 2019;26:520–528.
26. Boellaard R, Hristova I, Ettinger S, et al. EARL FDG-PET/CT accreditation program: Feasibility, overview and results of first 55 successfully accredited sites. *J Nucl Med*. 2013;54(suppl 2):498P–499P.