

Relative Contribution of Magnetic Resonance Imaging, Microelectrode Recordings, and Awake Test Stimulation in Final Lead Placement during Deep Brain Stimulation Surgery of the Subthalamic Nucleus in Parkinson's Disease

Henriette L. Frequin^{a,b} Maarten Bot^a José Dilai^b Marije N. Scholten^b
Miranda Postma^b Lodewijk J. Bour^b Maria Fiorella Contarino^{c,d} Rob M.A. de Bie^b
P. Rick Schuurman^a Pepijn van den Munckhof^a

^aDepartment of Neurosurgery, Amsterdam University Medical Centers, Academic Medical Center (AMC), Amsterdam, The Netherlands; ^bDepartment of Neurology and Clinical Neurophysiology, Amsterdam University Medical Centers, Academic Medical Center (AMC), Amsterdam, The Netherlands; ^cDepartment of Neurology, Haga Teaching Hospital, The Hague, The Netherlands; ^dDepartment of Neurology, Leiden University Medical Center (LUMC), Leiden, The Netherlands

Keywords

Parkinson's disease · Subthalamic nucleus · Deep brain stimulation · Magnetic resonance imaging · Microelectrode recordings · Awake test stimulation

Abstract

Introduction: For deep brain stimulation (DBS) surgery of the subthalamic nucleus (STN) in Parkinson's disease (PD), many centers employ visualization of the nucleus on magnetic resonance imaging (MRI), intraoperative microelectrode recordings (MER), and test stimulation in awake patients. The value of these steps is a subject for ongoing debate. In the current study, we determined the relative contribution of MRI targeting, multitrack MER, and awake test stimulation in final lead placement during STN DBS surgery for PD. **Methods:** Data on PD patients undergoing MRI-targeted STN DBS surgery with three-channel MER and awake test stimulation between February 2010 and January 2014 were analyzed to determine in which MER trajectory final leads were implanted and why this tract was chosen.

Results: Seventy-six patients underwent implantation of 146 DBS leads. In 92% of the STN, the final leads were implanted in one of the three planned channels. In 6%, additional channels were needed. In 2%, surgery was aborted before final lead implantation due to anxiety or fatigue. The final leads were implanted in the channels with the longest STN MER signal trajectory in 60% of the STN (38% of the bilaterally implanted patients). This was the central channel containing the MRI target in 39% of the STN (18% bilaterally). The most frequently noted reasons why another channel than the central channel was chosen for final lead placement were (1) a lower threshold for side effects (54%) and (2) no or a too short trajectory of the STN MER signal (40%) in the central channel. The latter reason correlated with larger 2D (x and y) errors in our stereotactic method. **Conclusions:** STN DBS leads were often not implanted in the MRI-planned trajectory or in the trajectory with the longest STN MER signal. Thresholds for side effects during awake test stimulation were decisive for final target selection in the majority of patients.

© 2020 The Author(s)
Published by S. Karger AG, Basel

Introduction

Bilateral deep brain stimulation (DBS) of the subthalamic nucleus (STN) is an effective surgical procedure for patients with advanced Parkinson's disease (PD) [1]. The precise identification of the STN target is paramount for maximizing therapeutic benefits while minimizing side effects [2]. Many DBS centers employ preoperative visualization of the STN on magnetic resonance imaging (MRI) followed by intraoperative microelectrode recordings (MER) and test stimulation in awake patients for STN localization. The relative value of these different steps in STN DBS surgery is a subject for ongoing debate. The use of MER facilitates delineation of the electrophysiological borders of the STN, but the number of MER penetrations may be associated with an increased risk of hemorrhage, while accurate STN localization on MRI could make awake test stimulation redundant, allowing for DBS surgery under general anesthesia [3, 4].

To determine the relative contributions of MRI, MER, and test stimulation in STN DBS lead placement, we reviewed surgical data on PD patients undergoing STN DBS surgery with MER and analyzed where the final DBS leads were implanted and why these locations were chosen.

Subjects and Methods

Microelectrode Recordings

Benabid developed an MER holder with five channels for micro/macro needles, with the central channel aiming at the planned surgical target, with additional anterior, lateral, posterior, and medial channels at a 2-mm distance from the central channel [5, 6]. In previous work on patients operated on between 2006 and 2010, we studied how often each of the five channels used for MER was chosen for final STN DBS lead implantation; the central channel was chosen in 50% of the cases, the anterior channel in 24%, the lateral channel in 10%, the posterior channel in 10%, and the medial channel in 6% of the cases [7].

Because of these results, we reduced the number of MER channels in the years thereafter to four (central, anterior, lateral, and posterior) and then three (central, anterior, and lateral). In some patients, we decided to use only one or two MER channels if there was considerable brain atrophy, or if blood vessels were present too closely to the planned trajectory.

Patients

Between February 2010 and January 2014, 120 consecutive PD patients underwent STN DBS surgery at our center. To reduce heterogeneity among the patients participating in the current analysis, we retrospectively collected and reviewed the data on consecutive PD patients who underwent MRI-targeted, three-channel MER-guided, awake DBS surgery of the STN. Consequently, 33

patients on whom one-, two-, or four-channel MER was performed, as well as 11 patients on whom no MER was conducted because of technical issues, were excluded from our analysis.

Surgical Procedure

Three to 6 months before the day of surgery, the patients underwent a 3-T nonstereotactic MRI (Siemens, Malvern, PA, USA) with axial and coronal T2-weighted and 3D volumetric T1-weighted sequences. On the day of surgery, the Leksell stereotactic G frame (Elekta AB, Stockholm, Sweden) was placed, and the patients underwent preoperative frame-based 1.5-T stereotactic MRI (Siemens) with axial and coronal T2-weighted and post-gadolinium 3D volumetric T1-weighted sequences. The preoperative 3-T MRI sequences were coregistered with a stereotactic volumetric T1-weighted sequence with the use of SurgiPlan software (Elekta AB).

STN target planning was started using standard stereotactic coordinates calculated from the mid-commissural point as follows: 11 mm lateral, 2 mm posterior, and 4 mm ventral. Target planning was subsequently adapted to individual anatomical configuration if necessary, based on red nucleus and STN representation on the T2 sequences. Trajectory planning was done using the post-gadolinium volumetric T1-weighted sequence. Entry points were chosen precoronal and 3–4 cm lateral from the midline on a suitable gyrus, and the trajectories were then adjusted to avoid penetration of ventricles, the caudate nucleus, and blood vessels.

All patients were operated on under local anesthesia in the supine position with the head elevated 20–30° to minimize the outflow of cerebrospinal fluid through the 12-mm burr hole trepanations. Cerebrospinal fluid outflow was further minimized by applying fibrin glue after the three cannulas containing microelectrodes (FHC, Bowdoin, ME, USA) had been placed in the holder. Multi-tract MER (Leadpoint; Medtronic, Shoreview, MN, USA) started 6 mm above the target point and the microelectrodes were manually advanced in 0.5-mm steps. The planned trajectory was the central channel, with additional anterior and lateral channels at a 2-mm distance.

Electrophysiological STN activity was considered to be present if a broadening of the background noise and a tonic and irregular discharge pattern with occasional bursts were detected during MER. The length and characteristics of the recordings were reviewed and interpreted by the neurophysiologist (L.J.B.) or neurophysiology physician assistant (J.D.), a neurologist (R.M.A.d.B. or M.F.C.), and a neurosurgeon (P.R.S. or P.v.d.M.). The recordings were extended 2–3 mm beyond the target point until the electrophysiological STN signal stopped or the characteristic signal indicating the substantia nigra pars reticulata was measured.

Therapeutic effects and side effects were evaluated by a neurologist (R.M.A.d.B. or M.F.C.) and a nurse practitioner (M.N.S. or M.P.) by monopolar electric test stimulation (60 μ s pulse duration; 130 Hz pulse frequency) through the macro-tip of the microelectrode at three different depths along the trajectories with a positive electrophysiological STN signal. After evaluation of the selected channels by test stimulation, the one with the largest therapeutic window, i.e., the lowest current threshold for improvement of PD symptoms and the highest threshold for side effects, was chosen for permanent DBS lead implantation (model 3389; Medtronic).

The DBS lead was secured to the skull with a Stimloc system (Medtronic). Adequate lead placement was evaluated with fluoros-

copy. Subsequent implantation of one or two implantable pulse generators was done in a subcutaneous or subpectoral pocket in the infraclavicular region under general anesthesia on the same day. On the postoperative day, a computed tomography (CT) scan with 2-mm slices was made to evaluate the lead position, and to rule out asymptomatic hemorrhage.

Data Analysis

Data on the side operated on first and second are presented separately. The accuracy of the stereotactic method was checked by comparing the intended lead localization (based on intraoperative MER and clinical testing) to the final lead position on postoperative CT coregistered to stereotactic MRI with the use of SurgiPlan software (Elekta AB): the x and y coordinates of the center of the final lead artifact on axial postoperative CT at the calculated stereotactic target depth were compared with the intraoperative x and y coordinates used. Both absolute x and y errors and 2D Euclidean ($\sqrt{x^2 + y^2}$) errors were calculated.

Values are presented as the mean \pm standard deviation. Ranges are mentioned if relevant. Fisher's exact tests (for analysis of 2×2 tables) were done when appropriate. Results with a $p < 0.05$ were considered statistically significant. IBM SPSS Statistics 24.0 was used for the calculations.

Results

Bilateral DBS placement was planned for 73 patients, whereas 3 patients underwent unilateral surgery (2 of them had received contralateral STN DBS surgery in previous years). The average age at surgery was 59 years, with an average disease duration of 12 years. The levodopa equivalent daily dose averaged $1,558 \pm 843$ mg (range 0–6,505). The Unified Parkinson's Disease Rating Scale (UPDRS) motor score averaged 41 (range 19–69) in the medication OFF stage, and 15 (range 0–35) in the medication ON stage.

Surgery

The STN was targeted at 11.0 ± 0.9 mm (range 9.2–13.6) lateral, 2.3 ± 0.6 mm (range 0.4–3.9) posterior, and 4.1 ± 0.4 mm (range 2.9–6.3) inferior relative to the mid-commissural point. Targeting did not differ between the left and the right side (data not shown). In 47 (64%) of the bilateral cases, surgery started on the left side. Of the 149 planned STN sides, we recorded 147 STN sides, and we implanted 146 STN DBS electrodes. In one patient with planned bilateral implantation, only one side was implanted successfully, whereas the other side was not recorded/implanted due to fatigue. In another patient with planned bilateral implantation, the procedure had to be aborted due to anxiety after MER on the first side had not shown typical electrophysiological STN activity in any channel.

Table 1. Trajectories with electrophysiological STN activity during MER

	STN operated on first ($n = 75$)	STN operated on second ($n = 71$) ¹
Central (= MRI target) channel		
Average length, mm	3.9 \pm 1.5	4.1 \pm 1.3 ($n = 70$)
No STN activity, n (%)	5 (7)	3 (4)
≤ 2.5 mm length, n (%)	13 (17)	7 (10)
2 mm anterior channel		
Average length	3.8 \pm 1.6	4.0 \pm 1.6
No STN activity, n (%)	7 (9)	5 (7)
≤ 2.5 mm length, n (%)	12 (16)	12 (17)
2 mm lateral channel		
Average length	3.7 \pm 1.7	3.6 \pm 1.8 ($n = 67$)
No STN activity, n (%)	7 (9)	8 (12)
≤ 2.5 mm length, n (%)	19 (25)	19 (28)
Extra channel(s) added, n	5	4
2 mm medial channel, n (%)	3 (4)	4 (6)
2.8 mm anteromedial channel, n (%)	1 (1)	–
4 mm anterior channel, n (%)	1 (1)	–

MER, microelectrode recordings; MRI, magnetic resonance imaging; STN, subthalamic nucleus. ¹ Based on the results observed in the STN operated on first, we adjusted the stereotactic coordinates for 3 STN operated on second (see main text for details) and chose a medial instead of a lateral channel for 2 STN operated on second. For another 2 STN operated on second, the lateral channel and the lateral + central channels, respectively, were omitted because of nearby blood vessels.

STN Operated on First

For 1 patient, the intraoperative notes of the MER on the side operated on first were lost. For the remaining 75 STN recorded first, the lengths of the trajectories with electrophysiological STN activity are shown in Table 1. Following test stimulation, it was decided to implant the final DBS lead in the central channel in 32 patients (43%), in the anterior channel in 27 patients (36%), and in the lateral channel in 11 patients (15%) (Fig. 1). In 3 patients (4%), a medial channel was added during test stimulation and chosen for final DBS lead implantation when test stimulation in the central, anterior, and lateral channels induced contralateral muscle contractions at 2–3 mA.

In 1 patient (1%), the first three-channel MER only showed typical STN activity over a length of 2 mm in the anterior channel. Test stimulation at 3.5 mA in this trajectory caused gaze paralysis. Therefore, the y coordinate of the target was moved 2 mm anterior, and a medial MER

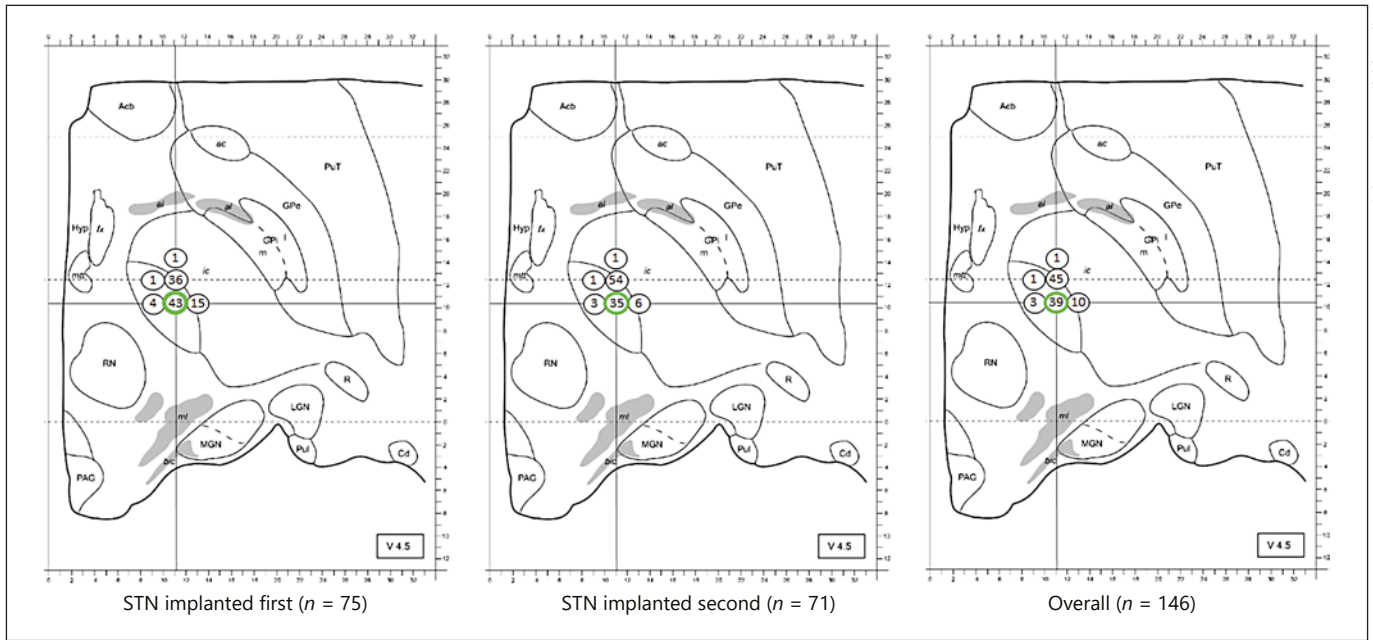


Fig. 1. Projection of channels chosen for final DBS lead implantation in 146 STN of 75 patients with advanced Parkinson's disease undergoing MRI targeting, three-channel MER (central [= MRI target], 2-mm anterior, and 2-mm lateral channels), and awake test stimulation into axial plate V4.5 of the *Stereotactic Atlas of the Human Thalamus and Basal Ganglia* [8]. Axial plate V4.5 corresponds to an axial plane located 4.5 mm below the mid-commissural point. The central channel (= MRI target) is encircled in green. The number in the circles is the percentage at which the final DBS lead was implanted in the corresponding channel of the 75 STN implanted first (left panel), of the 71 STN implanted second (middle panel), and of the 146 STN overall (right panel). *ac*, anterior commissure; *Acb*, nucleus accumbens; *al*, ansa lenticularis; *bic*, brachium of the inferior colliculus; *Cd*, caudate nucleus; *DBS*, deep brain stimulation; *fx*, fornix; *GPe*, external globus pallidus; *Gpi*, internal globus pallidus; *Hyp*, hypothalamus; *ic*, internal capsule; *LGN*, lateral geniculate nucleus; *MER*, microelectrode recordings; *MGN*, medial geniculate nucleus; *ml*, medial lemniscus; *MRI*, magnetic resonance imaging; *mtt*, mammillothalamic tract; *PAG*, periaqueductal gray area; *PuI*, inferior pulvinar; *PuT*, putamen; *R*, reticular thalamic nucleus; *RN*, red nucleus; *STN*, subthalamic nucleus.

channel was added. Here, a 4-mm trajectory of STN activity was recorded, and test stimulation up to 5 mA did not cause any side effects. Consequently, the final lead was implanted 2 mm anterior and 2 mm medial relative to the original target (anteromedial).

In another patient (1%), test stimulation at 2 mA caused gaze paralysis in both the central and the anterior channel. The *y* coordinate was moved 2 mm anterior, and test stimulation in the new anterior channel reduced the PD symptoms without causing any side effect. Thus, the final lead was implanted 4 mm anterior relative to the original target.

The length of STN MER activity of the channel chosen for final DBS electrode placement on the side operated on first was on average 4.6 ± 0.9 mm (range 1.5–6.0; $n = 71$).

STN Operated on Second

In 5 (7%) of the 71 bilaterally operated patients, it was decided intraoperatively to adjust the stereotactic coordi-

onate and/or MER approach for the second STN based on the results observed during MER and test stimulation on the side operated on first. In 2 patients, the *y* coordinate was moved 2 mm anterior, in 1 patient the *x* coordinate was moved 2 mm lateral. In 2 patients, a medial instead of a lateral channel was used. In 2 other patients, the lateral channel and the lateral plus central channels, respectively, were omitted due to the presence of blood vessels nearby these trajectories.

The lengths of the trajectories with electrophysiological STN activity of the 71 STN recorded second are shown in Table 1. Following test stimulation, it was decided to implant the final DBS lead in the central channel in 25 patients (35%), in the anterior channel in 38 patients (54%), and in the lateral channel in 4 patients (6%) (Fig. 1).

In 4 patients (6%), a medial channel was added during test stimulation and chosen for final DBS lead implantation when test stimulation in the central and the anterior

Table 2. Reasons why another than the central (= MRI target) channel was chosen for final DBS lead implantation

	STN operated on first (<i>n</i> = 42)	STN operated on second (<i>n</i> = 47)	Total (<i>n</i> = 89)
No or very short trajectory of the STN MER signal	11 (26)	7 (15)	18 (20)
Longer STN MER signal on other channel	9 (21)	9 (19)	18 (20)
Gaze paresis	6 (14)	10 (21)	16 (18)
At 2 mA	1	3	4
At 3 mA	2	5	7
At 4 mA	1	2	3
At 5 mA	2		2
Mouth contraction	5 (12)	8 (17)	13 (15)
At 1.5 mA	1	1	2
At 2 mA	1	2	3
At 3 mA	1	4	5
At 4 mA	2	1	3
Dysarthria	3 (7)	5 (11)	8 (9)
At 2 mA	1	2	3
At 3 mA	2	2	4
At 4 mA		1	1
Dizziness	3 (7)	2 (4)	5 (6)
At 2 mA	1		1
At 3 mA	1	2	3
At 4 mA	1		1
Warm/strange feeling	2 (5)		2 (2)
At 1 mA	1		1
At 2.5 mA	1		1
Chest pain	1 (2)		1 (1)
At 2 mA	1		1
Leg paresthesia	1 (2)		1 (1)
At 2 mA	1		1
Pupillary dilatation	1 (2)		1 (1)
At 1 mA	1		1
Only test stimulation in final channel (not central) first side		2 (4)	2 (2)
Worsening of PD symptoms		1 (2)	1 (1)
Central channel not explored		3 (6)	3 (3)
Stereotactic coordinates adjusted based on results first side		2 (2)	2
Due to blood vessel		1 (2)	1

Values denote *n* (%). DBS, deep brain stimulation; MER, microelectrode recordings; MRI, magnetic resonance imaging; PD, Parkinson's disease; STN, subthalamic nucleus.

channel induced, respectively, contralateral mouth contraction (at 1.5 mA), dysarthria (at 2/3 mA), or gaze paralysis (at 2 mA). The last patient was the one in whom the *x* coordinate was moved 2 mm lateral based on the results observed during MER and test stimulation on the side operated on first. The final medial DBS lead was thus in the originally planned central channel.

The patient experiencing dysarthria at 2 mA during test stimulation in the central and anterior channels was

one of the 2 patients in whom the *y* coordinate was moved 2 mm anterior based on the results observed during MER and test stimulation on the side operated on first; the medial channel added during test stimulation and chosen for final DBS lead implantation was thus 2 mm anterior and 2 mm medial relative to the originally planned target (anteromedial). In the other patient in whom the *y* coordinate was moved 2 mm anterior based on the results observed during MER and test stimulation on the side operated on

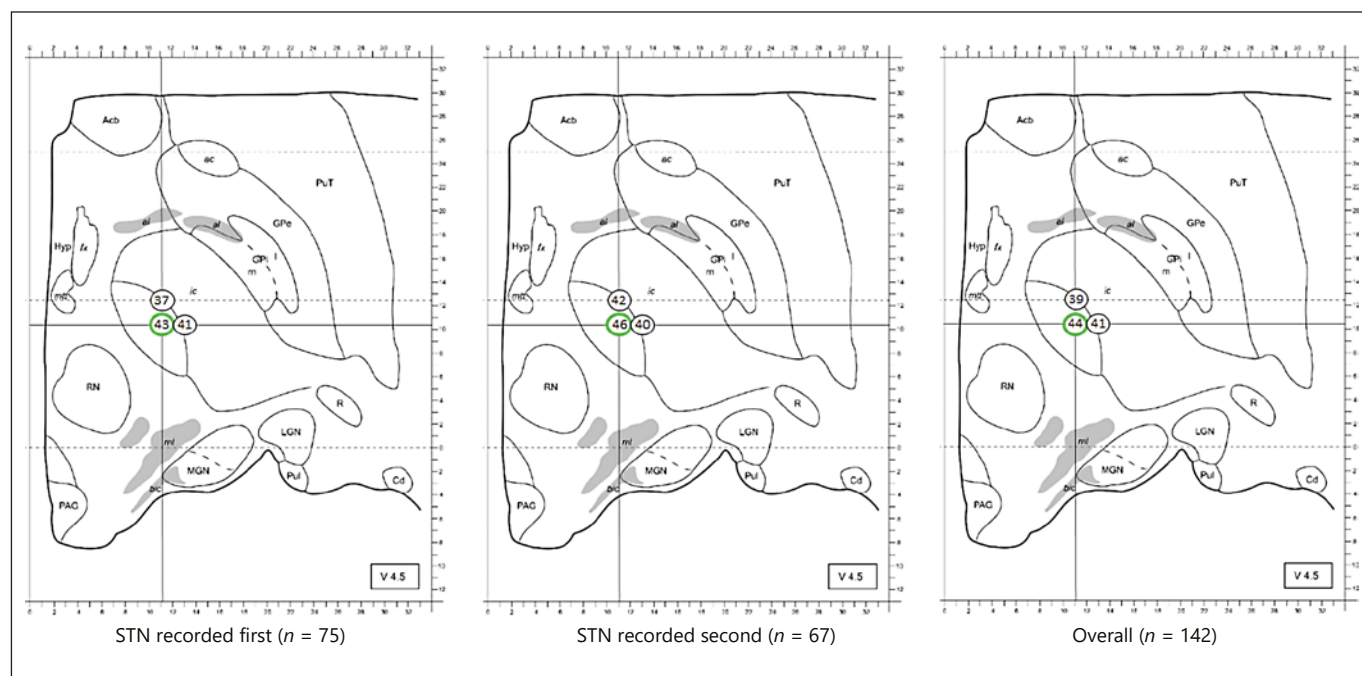


Fig. 2. Projection of MER channels employed during DBS surgery on 142 STN of 75 patients with advanced Parkinson's disease undergoing MRI targeting, three-channel MER (central [= MRI target], 2-mm anterior, and 2-mm lateral channels), and awake test stimulation into axial plate V4.5 of the *Stereotactic Atlas of the Human Thalamus and Basal Ganglia* [8]. Axial plate V4.5 corresponds to an axial plane located 4.5 mm below the mid-commissural point. The central channel (= MRI target) is encircled in

green. The number in the circles is the percentage at which the longest electrophysiological STN MER signal was recorded in the corresponding channel of the 75 STN operated on first (left panel), of the 67 STN operated on second (middle panel), and of the 142 STN overall (right panel). Total percentages exceed 100% due to multiple trajectories with equally long lengths of the STN signal. For abbreviations, see legend to Figure 1.

first, the final lead was implanted in the anterior channel (i.e., 4 mm anterior relative to the original target).

The length of STN MER activity of the channel chosen for final DBS lead placement on the side operated on second averaged 4.5 ± 1.0 mm (range 0–6.5; $n = 66$).

Proportion of Implantations in the Central (= MRI Target) Channel

Overall, the central channel was chosen for final DBS lead implantation in 57/146 STN (39%). Only 13 (18%) of the 71 bilaterally implanted patients received both final DBS leads in the central channel. Twenty (28%) received both leads in the anterior channel, none received both leads in the lateral channel, and the remaining 38 patients (54%) received the leads in a combined fashion of channels. Table 2 summarizes the 89 reasons why another than the central channel was chosen for final DBS lead implantation, which was based on either a better MER signal in another channel (40%) or a higher threshold for side effects (54%), but never on a superior effect of test stimulation on PD symptoms.

Proportion of Implantations in the MER Channel with the Longest Segment of the STN Signal

In the STN recorded first, one of the three channels exhibited the longest trajectory of the STN signal in 59/75 (79%) of the cases, while in 15/75 (20%) of the cases, two ($n = 13$) or three ($n = 2$) channels showed equally long trajectories of the STN signal, and in 1 patient (as stated before) none of the three channels exhibited typical electrophysiological STN activity. In 51/67 (76%) of the STN recorded second with central/anterior/lateral channel MER, one of the three channels exhibited the longest trajectory of the STN signal, whereas in 16/67 (24%) of the cases, two ($n = 13$) or three ($n = 3$) showed equally long trajectories of the STN signal. Figure 2 summarizes the results on the channels with the longest trajectory of recorded STN.

In 45/75 (60%) of the STN recorded first, the final DBS lead was implanted in (one of) the channel(s) exhibiting the longest trajectory of the STN signal. In 40/67 (60%) of the STN recorded second, the final DBS lead was implanted in (one of) the channel(s) exhibiting the longest trajec-

Table 3. Reasons why another than (one of) the channel(s) with the longest STN MER signal was chosen for final DBS lead implantation

	STN operated on first (<i>n</i> = 30)	STN operated on second (<i>n</i> = 27)	Total (<i>n</i> = 57)
STN MER signal on central channel only			
0.5 mm shorter, good anti-PD response	2 (7)	1 (4)	3 (5)
Gaze paresis	7 (23)	11 (41)	18 (32)
At 1 mA		2	2
At 2 mA	1	3	4
At 3 mA	4	4	8
At 4 mA	1	2	3
At 5 mA	1		1
Mouth contraction	4 (13)	5 (19)	9 (16)
At 1.5 mA	2	1	3
At 2 mA		2	2
At 3 mA		2	2
At 4 mA	1		1
At 5 mA	1		1
Dysarthria	10 (33)	1 (4)	11 (20)
At 2 mA	2		2
At 3 mA	4	1	5
At 4 mA	3		3
At 5 mA	1		1
Arm contraction	1 (3)	0 (0)	1 (2)
At 2 mA	1		1
Dizziness	1 (3)	0 (0)	1 (2)
At 4 mA	1		1
Warm/strange feeling	2 (7)	0 (0)	2 (4)
At 1 mA	1		1
At 2.5 mA	1		1
Chest pain	1 (3)	0 (0)	1 (2)
At 2 mA	1		1
No good anti-PD response	1 (3)	1 (4)	2 (4)
Nausea	1 (3)	2 (7)	3 (5)
At 1 mA	1		1
At 2 mA		1	1
At 3 mA		1	1
Only test stimulation in anterior channel (= final channel first side)		5 (19)	5 (9)
Blepharospasm		1 (4)	1 (2)
At 3 mA		1	1

Values denote *n* (%). DBS, deep brain stimulation; MER, microelectrode recordings; MRI, magnetic resonance imaging; PD, Parkinson's disease; STN, subthalamic nucleus.

tory of STN signal. Twenty-seven out of 71 bilaterally implanted patients (38%) received both final leads in the channel with the longest STN MER signal. Table 3 summarizes the 57 reasons why another than (one of) the channel(s) with the longest MER signal was chosen for final DBS lead implantation, which was mostly based on lower thresholds for side effects (82%), but hardly on a superior anti-PD effect (4%).

Accuracy of the Stereotactic Method

In 4 bilaterally implanted patients, no reliable implantation errors could be calculated due to unreliable coregistration with the stereotactic MRI; in 2 cases, the postoperative CT contained too much intracranial air, and in the other cases, only postoperative CT with 5-mm slices was performed. For the remaining 138 leads, the mean *x* error was 0.11 ± 0.95 mm medial (range 2.60 mm medial to 2.20

Fig. 3. Projection of planned STN target (left panel) and the STN target corrected for the observed x and y implantation errors into axial plate V4.5 of the *Stereotactic Atlas of the Human Thalamus and Basal Ganglia* [8]. Axial plate V4.5 corresponds to an axial plane located 4.5 mm below the mid-commissural point. The STN was targeted at (on average) 11.0 mm lateral and 2.3 mm posterior relative to the mid-commissural point (left panel). The mean x implantation error was 0.11 mm medial, but ranged between 2.60 mm medial and 2.20 mm lateral; the mean y error was 0.66 mm posterior, but ranged between 3.10 mm posterior and 1.90 mm anterior (right panel). The lengths of the bars in the right panel indicate the range in the four directions. For abbreviations, see legend to Figure 1.

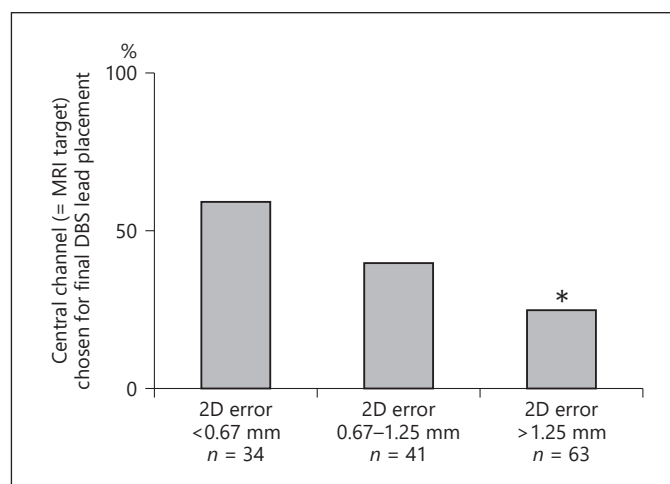
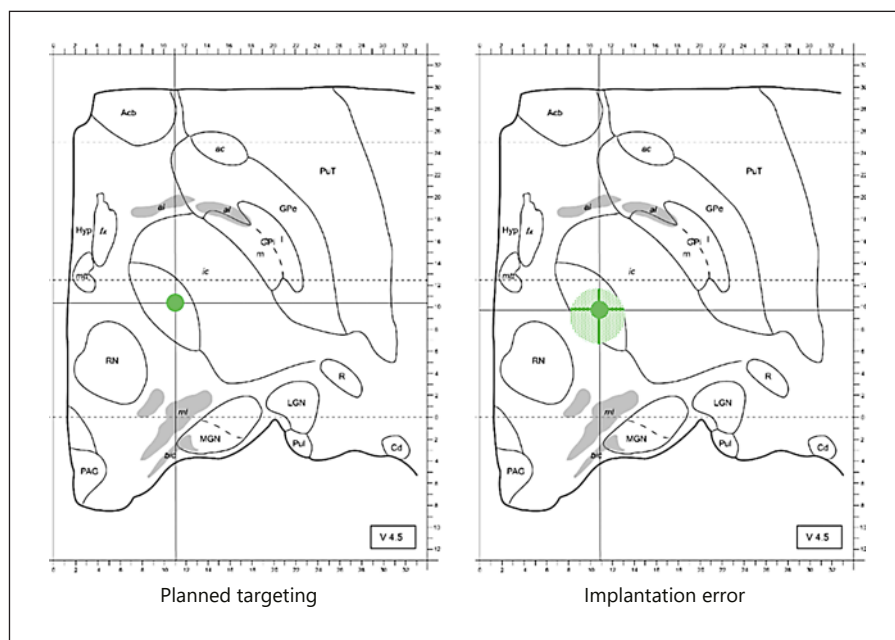


Fig. 4. Percentage of STN in which the final DBS lead was implanted in the central channel (= MRI target) relative to the observed Euclidean error between the final and the intended lead position, categorized by 2D error <0.67 mm, 2D error 0.67–1.25 mm, and 2D error >1.25 mm. * The difference in percentage between 2D error <0.67 mm and 2D error >1.25 mm was statistically significant (OR 4.2; 95% CI 1.7–10.2; $p = 0.001$). DBS, deep brain stimulation; MRI, magnetic resonance imaging; STN, subthalamic nucleus.

mm lateral) and the mean y error was 0.66 ± 0.85 mm posterior (range 3.10 mm posterior to 1.90 mm anterior) (Fig. 3).

The mean 2D Euclidean error between the final and the intended lead position was 1.25 ± 0.70 mm (range

0–3.22). The proportion of leads implanted in the central channel was significantly higher if the Euclidean error was ≤ 1.25 mm than if the Euclidean error was > 1.25 mm (49 vs. 27%; OR 2.6; 95% CI 1.3–5.4; $p < 0.01$) (Fig. 4). Among the central channels with ≤ 2.5 mm STN MER activity, the Euclidean error exceeded 1.25 mm more often than it did among the central channels with > 2.5 mm STN MER activity (67 vs. 42%; OR 2.7; 95% CI 1.0–7.7; $p < 0.05$).

Postoperative Course

One patient (1%) had a symptomatic subcortical hemorrhage manifesting in delirium. The patient recovered fully. In 3 patients, the postoperative CT scan showed an asymptomatic postoperative intracerebral hemorrhage. All 4 patients (5%) with intracerebral hemorrhage underwent bilateral three-channel MER without the need for adding extra channels. The reduction in levodopa equivalent daily dose after 14 ± 5 months (range 2–27) of STN DBS treatment averaged $48 \pm 24\%$ (range –25 to 100).

Discussion

We examined the relative contributions of MRI targeting, three-channel MER, and awake test stimulation in final lead placement during DBS surgery on 149 STN of 76 patients with advanced PD. In 92% of the STN, the final leads were indeed implanted in one of the three

planned channels, showing that the strategy of starting with three-channel MER is appropriate. In 3 STN (2%; 2 patients), surgery was aborted before final lead implantation due to anxiety or fatigue. The final leads were more often implanted in the channels with the longest STN MER signal trajectory than in the central channels.

The most frequently noted reasons why another channel than the one containing the MRI target was chosen for final lead placement were (1) a too low threshold for side effects caused by co-stimulation of the nearby internal capsule and (2) no or a too short trajectory of the STN MER signal in the central channel. The latter reason correlated with larger 2D (x and y) errors in our stereotactic method. The most frequently noted reason why another than the channel with the longest STN MER signal was chosen for final lead placement was a too low threshold for side effects caused by co-stimulation of the nearby internal capsule.

The Value of MER and MRI during STN DBS Surgery

In PD patients, there is a strong coherence within the basal ganglia and thalamocortical circuits that can be measured in the dorsolateral, sensorimotor part of the STN in the beta range (13–30 Hz) [9, 10]. Precise placement of the DBS lead into or close to this part of the electrophysiological STN is required to ensure the efficacy of the treatment and to minimize adverse effects [2, 11, 12]. Intraoperative localization of the dorsolateral STN with the use of MER is therefore of great importance [13, 14]. A long length of the STN MER signal does, of course, not automatically indicate proper positioning within the dorsolateral STN. Besides a sudden increase in background noise level while moving from the zona incerta and lenticular fasciculus (field H2) into the dorsolateral STN, one should also heed rhythmic bursts of beta range activity [15]. Furthermore, adding a lateral and an anterior MER channel to the MRI-targeted channel allows for increased spatial resolution of the surgical approach to the dorsolateral STN. Determining thresholds for co-stimulation of the nearby internal capsule may also provide important information on how lateral the STN is targeted.

The use of MER and the number of MER penetrations may be associated with an increased risk of hemorrhage [3]. Moreover, current MRI techniques enable direct targeting based on a patient's own brain anatomy [16, 17]. Many groups reported good clinical outcomes of MRI-guided STN DBS without the use of MER [18, 19]. However, not all MRI sequences properly display the dorsolateral STN, and discrepancies were reported when comparing dorsal STN borders on MRI with the electrophysiological STN [20–23]. In our cohort, unexpectedly

short STN MER trajectories (≤ 2.5 mm) were seen in 13% of the central (= MRI target) channels. In a recent study, Lozano et al. [24] reported a similar (20%) mismatch between the expected STN on 1.5-T MRI and MER findings. They defined mismatch as an STN MER trajectory < 4 mm. In our cohort, trajectories < 4 mm occurred in 31% of the cases. Inaccuracy in the stereotactic methods may explain part of such mismatch. In our cohort, we noted significant imprecision in the stereotactic method, with final DBS leads scattered around the intended target with an inaccuracy of up to several millimeters. Similar inaccuracies with various stereotactic frames have been reported by other groups [25–27]. Besides the ability of MER to properly identify the dorsolateral STN, it thus may also supply important intraoperative feedback on the accuracy of the stereotactic method applied.

As stated above, MER have been suggested to increase the risk of hemorrhage (although we experienced a remarkably higher percentage of symptomatic hemorrhages during non-MER macrostimulation-only thalamic DBS in essential tremor patients [28]). Reducing the number of MER channels to three per side is an acceptable tradeoff to keep this risk as low as possible while still benefiting from the useful information provided by MER. Future studies comparing STN borders on ultrahigh-field MRI to the electrophysiological STN during DBS surgery with verified low inaccuracy are needed to determine whether MRI can replace MER in localization of the dorsolateral STN.

The Value of Awake Test Stimulation during STN DBS

In our current cohort, the observed side effects during awake test stimulation were decisive for final target selection in the majority of patients. Most of the observed side effects were thought to originate from co-stimulation of the nearby internal capsule. Of course, one may question the clinical relevance of the various observed side effects and of the stimulation threshold at which they occurred; a channel with mouth contraction or dysarthria at 2 mA may not be a wise choice for final DBS lead placement, but a channel with gaze paresis at 5 mA and good anti-PD effect might have been a good choice. It is rare to employ STN DBS above 4 mA at our outpatient clinic.

Performing DBS surgery under general anesthesia could offer a major advantage for patient comfort. In recent years, several groups have reported good clinical outcomes in parkinsonian patients undergoing STN DBS surgery under general anesthesia [4, 29, 30]. To investigate if STN DBS for PD under general anesthesia im-

proves the outcome by lessening postoperative cognitive, mood and behavioral adverse effects, shortening surgical time and hospital admittance, and producing a symptomatic and functional improvement comparable to that with surgery under local anesthesia, we started a randomized controlled trial [31]. A total of 110 patients were randomized between surgery under local and surgery under general anesthesia, and results are expected to be reported by the end of 2020.

Limitations of the Study

The present study has several limitations. First, the clinical outcome of the patients of the currently studied cohort was not analyzed according to a standardized protocol employing UPDRS scores for all patients. The long-term clinical effect of the variable choice of channels for implantation of the final DBS lead therefore could not be determined. Second, we measured the STN MER signal in 0.5-mm steps. With the real dorsal border of the STN starting between 0 and 0.49 mm above our measured dorsal border, and the real ventral border of the STN continuing between 0 and 0.49 mm below our measured ventral border, our measured STN trajectory lengths underestimated the real lengths by 0–0.98 mm. Third, small image fusion errors may have occurred during coregistration of the different MRI sequences and CT images, thereby potentially influencing the reported implantation errors.

Conclusions

DBS leads in PD patients undergoing MRI-targeted STN DBS surgery with three-channel MER and awake test stimulation were implanted in the planned trajectories based on MRI in only 39% of the STN (18% bilaterally), and in the channel with the longest STN MER signal in 60% (38% bilaterally). The thresholds for internal capsule-related side effects during test stimulation were decisive for final target selection in the majority of patients. However, whether the decision to change the final lead location from the initially planned target based on side effect thresholds is related to the clinical outcome will have to be determined by future research.

ally), and in the channel with the longest STN MER signal in 60% (38% bilaterally). The thresholds for internal capsule-related side effects during test stimulation were decisive for final target selection in the majority of patients. However, whether the decision to change the final lead location from the initially planned target based on side effect thresholds is related to the clinical outcome will have to be determined by future research.

Statement of Ethics

Formal approval for this retrospective observational study was waived by the institutional ethical review board of our hospital, and patient consent was not required.

Disclosure Statement

The DBS team of the AMC received unrestricted research grants from Medtronic and received financial compensation for teaching courses for the European Continuing Medical Training program. M.B. and P.v.d.M. received travel grants from Medtronic; M.F.C. received speaking fees from Medtronic and AbbVie; R.M.A.d.B. reports research grants from ZonMw, Parkinson Vereniging (Dutch patient organization), Stichting Parkinson-fonds (charitable foundation), Stichting Parkinson Nederland (charitable foundation), and unrestricted research grants from GE Health and Medtronic; P.R.S. acts as independent advisor for Medtronic and Boston Scientific; H.L.F., J.D., M.N.S., M.P., and L.J.B. have no disclosures.

Author Contributions

H.L.F., M.B., and P.v.d.M. designed the study; M.B., J.D., M.N.S., M.B., L.J.B., M.F.C., R.M.A.d.B., P.R.S., and P.v.d.M. were involved in collection of the data; H.L.F., M.B., and P.v.d.M. interpreted the data; H.L.F. and P.v.d.M. wrote the manuscript. All authors critically reviewed the results and the manuscript.

References

- 1 Odekerken VJ, van Laar T, Staal MJ, Mosch A, Hoffmann CF, Nijssen PC, et al. Subthalamic nucleus versus globus pallidus bilateral deep brain stimulation for advanced Parkinson's disease (NSTAPS study): a randomised controlled trial. *Lancet Neurol*. 2013 Jan; 12(1):37–44.
- 2 Guehl D, Cuny E, Benazzouz A, Rougier A, Tison F, Machado S, et al. Side-effects of subthalamic stimulation in Parkinson's disease: clinical evolution and predictive factors. *Eur J Neurol*. 2006 Sep;13(9):963–71.
- 3 Zrinzo L, Foltynie T, Limousin P, Hariz MI. Reducing hemorrhagic complications in functional neurosurgery: a large case series and systematic literature review. *J Neurosurg*. 2012 Jan;116(1):84–94.
- 4 Nakajima T, Zrinzo L, Foltynie T, Olmos IA, Taylor C, Hariz MI, et al. MRI-guided subthalamic nucleus deep brain stimulation without microelectrode recording: can we dispense with surgery under local anaesthesia? *Stereotact Funct Neurosurg*. 2011;89(5):318–25.
- 5 Benabid AL, Krack PP, Benazzouz A, Limousin P, Koudsie A, Pollak P. Deep brain stimulation of the subthalamic nucleus for Parkinson's disease: methodologic aspects and clinical criteria. *Neurology*. 2000;55(12 Suppl 6):S40–4.
- 6 Benazzouz A, Breit S, Koudsie A, Pollak P, Krack P, Benabid AL. Intraoperative microrecordings of the subthalamic nucleus in Parkinson's disease. *Mov Disord*. 2002;17(S3 Suppl 3):S145–9.
- 7 Bour LJ, Contarino MF, Foncke EM, de Bie RM, van den Munckhof P, Speelman JD, et al. Long-term experience with intraoperative microrecording during DBS neurosurgery in STN and GPi. *Acta Neurochir (Wien)*. 2010 Dec;152(12):2069–77.
- 8 Morel A. *Stereotactic atlas of the human thalamus and basal ganglia*. New York: Informa Healthcare; 2007.

- 9 Gatev P, Darbin O, Wichmann T. Oscillations in the basal ganglia under normal conditions and in movement disorders. *Mov Disord*. 2006 Oct;21(10):1566–77.
- 10 Weinberger M, Hutchison WD, Dostrovsky JO. Pathological subthalamic nucleus oscillations in PD: can they be the cause of bradykinesia and akinesia? *Exp Neurol*. 2009 Sep; 219(1):58–61.
- 11 Hamel W, Fietzek U, Morsnowski A, Schrader B, Herzog J, Weinert D, et al. Deep brain stimulation of the subthalamic nucleus in Parkinson's disease: evaluation of active electrode contacts. *J Neurol Neurosurg Psychiatry*. 2003 Aug;74(8):1036–46.
- 12 Bot M, Schuurman PR, Odekerken VJ, Verhagen R, Contarino FM, De Bie RM, et al. Deep brain stimulation for Parkinson's disease: defining the optimal location within the subthalamic nucleus. *J Neurol Neurosurg Psychiatry*. 2018 May;89(5):493–8.
- 13 Zaidel A, Spivak A, Grieb B, Bergman H, Israel Z. Subthalamic span of beta oscillations predicts deep brain stimulation efficacy for patients with Parkinson's disease. *Brain*. 2010 Jul;133(Pt 7):2007–21.
- 14 Verhagen R, Bour LJ, Odekerken VJ, van den Munckhof P, Schuurman PR, de Bie RM. Electrode location in a microelectrode recording-based model of the subthalamic nucleus can predict motor improvement after deep brain stimulation for Parkinson's disease. *Brain Sci*. 2019 Mar;9(3):E51.
- 15 Cagnan H, Dolan K, He X, Contarino MF, Schuurman R, van den Munckhof P, et al. Automatic subthalamic nucleus detection from microelectrode recordings based on noise level and neuronal activity. *J Neural Eng*. 2011 Aug;8(4):046006.
- 16 Richter EO, Hoque T, Halliday W, Lozano AM, Saint-Cyr JA. Determining the position and size of the subthalamic nucleus based on magnetic resonance imaging results in patients with advanced Parkinson disease. *J Neurosurg*. 2004 Mar;100(3):541–6.
- 17 Ashkan K, Blomstedt P, Zrinzo L, Tisch S, Yousry T, Limousin-Dowsey P, et al. Variability of the subthalamic nucleus: the case for direct MRI guided targeting. *Br J Neurosurg*. 2007 Apr;21(2):197–200.
- 18 Aviles-Olmos I, Kefalopoulou Z, Tripoliti E, Candelario J, Akram H, Martinez-Torres I, et al. Long-term outcome of subthalamic nucleus deep brain stimulation for Parkinson's disease using an MRI-guided and MRI-verified approach. *J Neurol Neurosurg Psychiatry*. 2014 Dec;85(12):1419–25.
- 19 Lee PS, Weiner GM, Corson D, Kappel J, Chang YF, Suski VR, et al. Outcomes of interventional-MRI versus microelectrode recording-guided subthalamic deep brain stimulation. *Front Neurol*. 2018 Apr;9:241.
- 20 Bot M, Bour L, de Bie RM, Contarino MF, Schuurman PR, van den Munckhof P. Can we rely on susceptibility-weighted imaging for subthalamic nucleus identification in deep brain stimulation surgery? *Neurosurgery*. 2016 Mar;78(3):353–60.
- 21 Verhagen R, Schuurman PR, van den Munckhof P, Contarino MF, de Bie RM, Bour LJ. Comparative study of microelectrode recording-based STN location and MRI-based STN location in low to ultra-high field (7.0 T) T2-weighted MRI images. *J Neural Eng*. 2016 Dec;13(6):066009.
- 22 Bus S, van den Munckhof P, Bot M, Pal G, Ouyang B, Sani S, et al. Borders of STN determined by MRI versus the electrophysiological STN. A comparison using intraoperative CT. *Acta Neurochir (Wien)*. 2018 Feb;160(2):373–83.
- 23 Nowacki A, Debove I, Fiechter M, Rossi F, Oertel MF, Wiest R, et al. Targeting accuracy of the subthalamic nucleus in deep brain stimulation surgery: comparison between 3 T T2-weighted magnetic resonance imaging and microelectrode recording results. *Oper Neurosurg (Hagerstown)*. 2018 Jul;15(1):66–71.
- 24 Lozano CS, Ranjan M, Boutet A, Xu DS, Kucharczyk W, Fasano A, et al. Imaging alone versus microelectrode recording-guided targeting of the STN in patients with Parkinson's disease. *J Neurosurg*. 2018 [Epub ahead of print].
- 25 Bjartmarz H, Rehnrona S. Comparison of accuracy and precision between frame-based and frameless stereotactic navigation for deep brain stimulation electrode implantation. *Stereotact Funct Neurosurg*. 2007;85(5):235–42.
- 26 Kelman C, Ramakrishnan V, Davies A, Holloway K. Analysis of stereotactic accuracy of the Cosman-Robert-Wells frame and Nexframe frameless systems in deep brain stimulation surgery. *Stereotact Funct Neurosurg*. 2010;88(5):288–95.
- 27 Bot M, van den Munckhof P, Bakay R, Sierens D, Stebbins G, Verhagen Metman L. Analysis of stereotactic accuracy in patients undergoing deep brain stimulation using Nexframe and the Leksell frame. *Stereotact Funct Neurosurg*. 2015;93(5):316–25.
- 28 Bot M, van Rootselaar F, Contarino MF, Odekerken V, Dijk J, de Bie R, et al. Deep brain stimulation for essential tremor: aligning thalamic and posterior subthalamic targets in 1 surgical trajectory. *Oper Neurosurg (Hagerstown)*. 2018 Aug;15(2):144–52.
- 29 Fluchere F, Witjas T, Eusebio A, Bruder N, Giorgi R, Leveque M, et al. Controlled general anaesthesia for subthalamic nucleus stimulation in Parkinson's disease. *J Neurol Neurosurg Psychiatry*. 2014 Oct;85(10):1167–73.
- 30 Tsai ST, Chen TY, Lin SH, Chen SY. Five-year clinical outcomes of local versus general anesthesia deep brain stimulation for Parkinson's disease. *Parkinsons Dis*. 2019 Jan;2019:5676345.
- 31 Holewijn RA, Verbaan D, de Bie RM, Schuurman PR. General Anesthesia versus Local Anesthesia in Stereotaxy (GALAXY) for Parkinson's disease: study protocol for a randomized controlled trial. *Trials*. 2017 Sep; 18(1):417.