

Dynamic knee imaging using 4D self-gated MRI with Compressed Sensing reconstruction

Valentina Mazzoli^{1,2,3}, Jasper Schoormans⁴, Martijn Froeling⁵, Andre M Sprengers¹, Klaas Nicolay², Bram F Coolen⁴, Aart J Nederveen³, Gustav J Strijkers^{3,4}, Nico Verdonchot¹

¹Orthopaedic Research Lab, Radboud UMCN, Nijmegen, The Netherlands, ²Biomedical NMR, Department of Biomedical Engineering, Eindhoven University of Technology, Eindhoven, The Netherlands, ³Department of Radiology, Academic Medical Center, Amsterdam, The Netherlands, ⁴Biomedical Engineering and Physics, Academic Medical Center, Amsterdam, The Netherlands, ⁵Department of Radiology, University Medical Center Utrecht, Utrecht, The Netherlands

Disclosures: V. Mazzoli: None. J. Schoormans: None. M. Froeling: None. A.M. Sprengers: None. K. Nicolay: None. B.F. Coolen: None. A.J. Nederveen: None. G.J. Strijkers: None. N. Verdonchot: None.

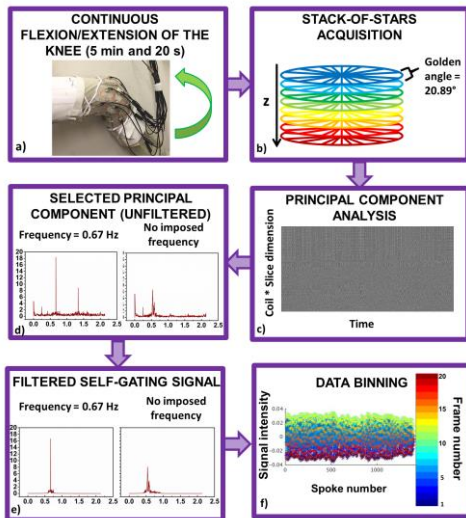


Figure 1: a) Volunteers perform flexion/extension continuously with the coil wrapped around their knees. b) Data is acquired using a stack-of-stars acquisition with zy ordering approach. c) The gating signal is extracted using PCA. d) The component with the highest energy content in the defined bands (0.6Hz-0.75 Hz motion with instruction and 0.45Hz – 0.9Hz for the motion without instructions), e) is band-pass filtered and f) used to assign each radial spoke to the corresponding time frame, using phase binning.

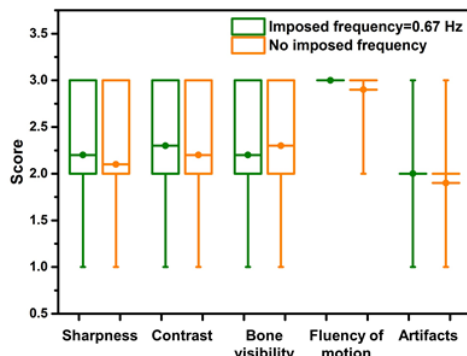


Figure 3: Results of scoring of the 4D movies by 2 MSK imaging experts. No statistical difference was observed in terms of sharpness, contrast, bone visibility, fluency of motion and presence of artifacts when the instructed frequency was 0.67 Hz, as compared to free movement.

tibiofemoral kinematic in healthy subjects which makes use of a kooshball encoding scheme and constant monitoring of knee flexion angle, which is retrospectively used for sorting radial spokes into several frames. Using our method, we were able to obtain 4D high resolution of the knee without the need for external hardware for gating. PCA showed to be a robust method to extract self-gating signal even for uninstructed motion. Further work will focus on accurate extraction of kinematics parameters from the obtained 4D data.

SIGNIFICANCE: this work shows the possibility to obtain 4D MR images of the knee during motion without the use of any additional device. The ability of visualizing the different structures in the knee during motion could provide radiologist with additional diagnostic information. The self-gating method is robust, therefore the technique is potentially suitable also for patients that due to pain may find difficult to exactly comply with instructions.

REFERENCES: [1] S. Wundrak et al IEEE Transactions on Medical Imaging, vol. 34, no. 6, pp. 1262-1269, 2015 [2] L. Feng et al. Magn. Reson. Med., 75: 775–788, 2016 [3] BART: version 0.3.01 (2016) DOI: 10.5281/zenodo.50726 [4] J. Kaiser, Magn Reson Med, 69: 1310–1316, 2013

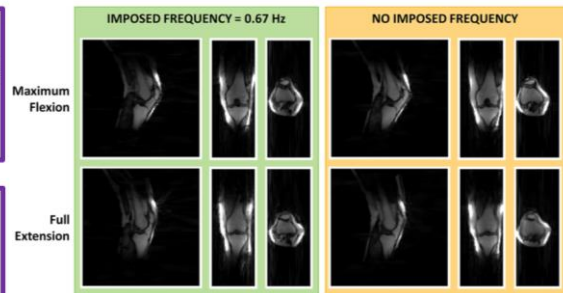


Figure 2: 2 different reconstructed dynamic frames (out of 20) representing the maximum achieved flexion and the full extension for a volunteer. Sagittal, coronal and transverse views are presented. The left images were acquired when the subject was instructed to move at 0.67 Hz, while during the acquisition of the right images the subject was free to move at her own preferred pace.

freely moving knee without a need for external triggering. The protocol is based on a self-gated 4D stack-of-stars radial sequence with compressed sensing reconstruction. To evaluate the effects of non-uniform motion and poor coordination skills on the quality of the reconstructed images, we performed a comparison between fully free movement and movement instructed by a visual cue.

METHODS: The dominant knee of 5 female volunteers (mean age=27±1 kg mean weight=61±6 kg) with no history of knee injury or pain was scanned. The subjects were placed supine on the scanner table, with a triangular-shaped support underneath their knees, and they were asked to perform a knee flexion/extension task 2 times. At first, the subjects were shown a movie of a ball bouncing up and down on a screen at 0.67 Hz. Afterwards, the screen in the MR room was turned off and subjects were asked to repeat the flexion/extension task at their own pace, without further visual instructions. The dynamic scans were obtained using a golden angle stack-of-stars radial sequence implemented on a 3T Philips Ingenia scanner. Sequence parameters were: matrix size = 160x160x47, voxel size=1.5x1.5x3 mm³, FOV=240x240x141 mm³, TR=3.9 ms, TE=1.3 ms. A total of 1410 spokes was acquired for each stack, with a tiny golden angle increment of ~20.89°. The acquisition was done continuously during 5 minutes and 20 seconds of knee flexion/extension. All acquisitions were performed using a custom built 15 ch flexible coil array (MR Coils BV, The Netherlands) (Figure 1a). Image reconstruction was performed in Matlab. The synchronization signal required for self-gating was derived from the center of k-space of the 3 middle slices, after inverse Fourier transformation in the z-direction. The trigger extraction was based on Principal Component Analysis (PCA), to determine the most common signal variations from the coil elements. The Principal Component representing knee motion was then selected as the one with the highest peak in the selected frequency band (Figure 1). The knee motion was subsequently binned in 20 motion states². We used the BART toolbox³ to perform a parallel-imaging CS reconstruction. The movies obtained with and without instructions were compared by two blinded MDs with experience in MSK MR, in terms of sharpness, contrast, bone visibility, fluency of motion, and presence of artifacts (0=insufficient, 3=diagnostic quality).

RESULTS: Volunteers were able to perform the motion task very consistently when instructed via a visual cue (narrow frequency peak, Figure 1d). On the other hand, the lack of precise instructions led to a shift of the center motion frequency, together with a broadening of the peak. However, with PCA for self-gating, the frequency representing both instructed and uninstructed motion could be identified correctly and resulting images only showed minor motion blurring (Figure 2). No significant difference in image-quality was reported for the movies obtained with and without instructions (Figure 3).

DISCUSSION: Kaiser et al.⁴ have developed a 4D MRI imaging technique to study tibiofemoral kinematic in healthy subjects which makes use of a kooshball encoding scheme and constant monitoring of knee flexion angle, which is retrospectively used for sorting radial spokes into several frames. Using our method, we were able to obtain 4D high resolution of the knee without the need for external hardware for gating. PCA showed to be a robust method to extract self-gating signal even for uninstructed motion. Further work will focus on accurate extraction of kinematics parameters from the obtained 4D data.