

# The Rapidly Assessed Predictor of Intraoperative Damage (RAPID) Score

## An In-Clinic Predictive Model for High-Grade Acetabular Chondrolabral Disruption

Mario Hevesi,\* MD, David E. Hartigan,<sup>†</sup> MD, Isabella T. Wu,\* BA, Cody C. Wyles,\* MD, Vishal S. Desai,\* BS, Andre J. van Wijnen,\* PhD, Daniel B.F. Saris,\* MD, PhD, Bruce A. Levy,\* MD, and Aaron J. Krych,\*<sup>‡</sup> MD

*Investigation performed at the Mayo Clinic, Rochester, Minnesota, USA*

**Background:** The preoperative assessment of cartilage lesions is critical to surgical planning and decision making. The accurate radiographic determination of acetabular cartilage damage has remained elusive for modern imaging modalities, including magnetic resonance imaging (MRI) and magnetic resonance arthrography (MRA). While risk factors have been individually described, no multivariable system exists for predicting high-grade cartilage damage.

**Purpose:** To determine the preoperative predictors of grade 3 to 4 acetabular labrum articular disruption (ALAD) lesions.

**Study Design:** Case-control study; Level of evidence, 3. Cohort study (diagnosis); Level of evidence, 1.

**Methods:** Retrievable radiographs were reviewed from primary hip arthroscopic procedures performed at 2 high-volume institutions between December 2007 and April 2017. The predictive value of demographic and radiographic factors for the intraoperative documentation of ALAD grade 3 to 4 damage was analyzed and entered into a multivariable model, and a statistically guided scoring system for the damage risk was created using the Akaike information criterion. The scoring system was then prospectively validated on 167 patients who underwent primary hip arthroscopy between April 2017 and February 2018.

**Results:** A total of 652 primary hip arthroscopic procedures in 614 patients (390 female, 224 male; mean age,  $33.2 \pm 12.5$  years; mean body mass index,  $26.9 \pm 5.5$  kg/m<sup>2</sup>) from 2007 to 2017 were analyzed. Male sex (odds ratio [OR], 3.11;  $P < .01$ ), age  $\geq 35$  years (OR, 1.96;  $P < .01$ ), cam morphology (alpha angle  $>55^\circ$ ) (OR, 2.96;  $P < .01$ ), and Tönnis grade 1 to 2 (grade 1: OR, 4.14;  $P < .01$ , and grade 2: OR, 9.29;  $P < .01$ ) were univariate risk factors for intraoperatively documented high-grade damage. A multivariable scoring system, the Rapidly Assessed Predictor of Intraoperative Damage (RAPID) score (0-5 points), was generated based on sex, Tönnis grade, and cam morphology. Patients with increasing RAPID scores had an increasing risk of damage, with a 10.5% risk for those with 0 points and an 88.0% risk for those with 5 points ( $P < .01$ ). The area under the curve was 0.75 for the study group and 0.76 for the validation group ( $P = .94$ ).

**Conclusion:** While preoperative MRI has diagnostic value for hip arthroscopic surgery, the RAPID score provides added benefit as a readily employable, in-clinic system for predicting high-grade cartilage damage. The discriminatory value of the RAPID score compares favorably with previous MRI and MRA studies. This information will help the clinician and patient plan for high-grade damage and identify potential targets for cartilage treatment.

**Keywords:** chondrolabral damage; hip arthroscopic surgery; imaging; FAI

A chondrolabral injury is manifested as progressive shear-induced separation of acetabular cartilage from the subchondral plate near the chondrolabral junction.<sup>14,24</sup> Mild forms of the disease can consist of isolated cartilage softening, whereas progressive disease leads to peel back,

generation of large flaps, and subsequent full-thickness cartilage loss. Intraoperative visualization of damage occurs commonly during hip arthroscopic surgery and open hip preservation surgery, with rates in femoroacetabular impingement (FAI) and dysplasia series ranging from 33% to 68%.<sup>2,4,22,26,29</sup> Given the significant influence of chondrolabral injuries on perioperative planning and preparation for potential cartilage intervention such as microfracture or future cell-based treatment options, the ability

The Orthopaedic Journal of Sports Medicine, 6(10), 2325967118799068  
DOI: 10.1177/2325967118799068  
© The Author(s) 2018

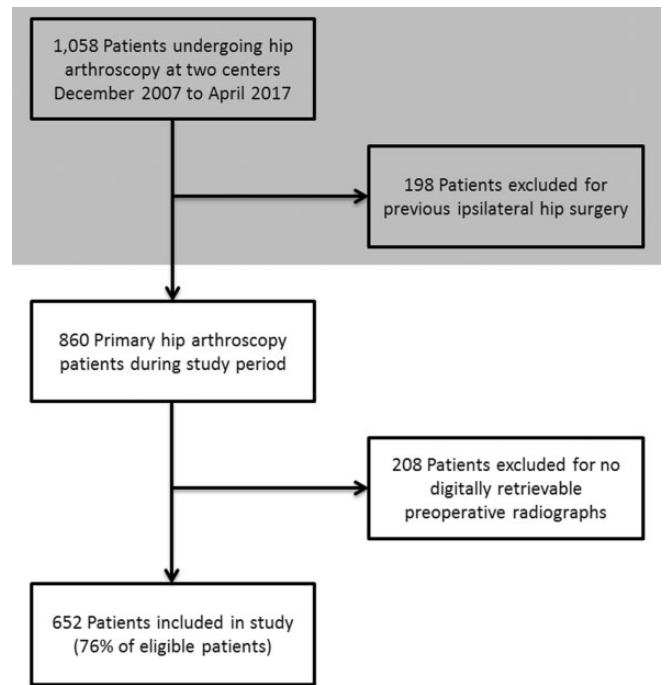
This open-access article is published and distributed under the Creative Commons Attribution - NonCommercial - No Derivatives License (<http://creativecommons.org/licenses/by-nc-nd/4.0/>), which permits the noncommercial use, distribution, and reproduction of the article in any medium, provided the original author and source are credited. You may not alter, transform, or build upon this article without the permission of the Author(s). For article reuse guidelines, please visit SAGE's website at <http://www.sagepub.com/journals-permissions>.

to predict which patients have high-grade cartilage damage would be of significant clinical utility, both for preoperative planning and possible prognostication.<sup>15,18,25</sup>

To date, both simple radiographic and advanced imaging modalities, including magnetic resonance imaging (MRI), have yielded little in the way of diagnostic accuracy or precision.<sup>17</sup> In the 2018 study by Rajeev et al<sup>24</sup> using gadolinium injected under fluoroscopic guidance, the sensitivity of magnetic resonance arthrography (MRA) for predicting damage was 7%, with 98% specificity. The overall diagnostic accuracy was 73.5%, and the area under the curve (AUC) for detecting damage was 0.52. These results, which demonstrate very low sensitivity but high specificity, mirror others, which have noted sensitivity ranging from 22% to 30%.<sup>2,22</sup> Without a full-thickness cartilage defect or subchondral cyst to allow for highly specific fluid accumulation under the delaminated area, it is difficult to visualize these pathological changes without direct articular interrogation and dynamic probing.

Male sex, age, and presence of a cam lesion have all been described as individual risk factors for high-grade acetabular damage, and the odds ratio (OR) for each of these risk factors has been published by high-volume hip arthroscopic surgery groups.<sup>2,3,12,26</sup> However, to date, no validated multivariable scoring system has outlined an approach for simultaneously assessing the risk factors that may be present in any given patient. This information is vital for preoperative discussion with the patient and planning. If a cartilage treatment such as microfracture is performed, the intraoperative surgical procedure and postoperative rehabilitation are significantly altered for the surgeon and patient.<sup>23</sup> Preoperative knowledge of these defects is essential but currently lacking.

Therefore, the purpose of this study was to (1) describe easily assessed preoperative risk factors for intraoperatively visualized high-grade chondrolabral damage, (2) generate a readily employable, in-clinic scoring system with which patients can be assessed for the likelihood of chondrolabral damage, and (3) apply the scoring system to a prospectively collected validation cohort. Our hypotheses were that (1) established risk factors such as sex, cam morphology, and Tönnis grade would predict high-grade damage; (2) using multiple factors, a scoring system with a significant preoperative predictive value would be generated; and (3) the resultant score would demonstrate satisfactory performance in the prospectively collected validation cohort.



**Figure 1.** Inclusion and exclusion of patients based on study criteria.

## METHODS

### Study Population and Design

This intraoperative and radiographic study included all patients undergoing hip arthroscopic surgery after the failure of comprehensive nonoperative management at 2 high-volume hip arthroscopic surgery centers (Mayo Clinic in Rochester, Minnesota; Mayo Clinic in Phoenix, Arizona). Patients consented to participate in research after institutional review board approval. Inclusion criteria consisted of (1) primary hip arthroscopic surgery between December 2007 and April 2017, (2) preoperative hip radiographs, and (3) written informed consent for research participation. Exclusion criteria consisted of (1) no digitally retrievable preoperative radiographs and (2) previous ipsilateral hip surgery (Figure 1). A second prospective cohort of patients who underwent surgery between April 2017 and February 2018 with the above-described inclusion and exclusion criteria served as a validation group for the scoring system

†Address correspondence to Aaron J. Krych, MD, Department of Orthopedic Surgery, Mayo Clinic, 200 First Street SW, Rochester, MN 55905, USA (email: krych.aaron@mayo.edu) (Twitter: @DrKrych).

\*Department of Orthopedic Surgery, Mayo Clinic, Rochester, Minnesota, USA.

†Department of Orthopedic Surgery and Sports Medicine, Mayo Clinic, Phoenix, Arizona, USA.

One or more of the authors has declared the following potential conflict of interest or source of funding: M.H. has received hospitality payments from DePuy. D.E.H. has received educational support from Arthrex and Smith & Nephew and hospitality payments from Desert Mountain Medical and Stryker. D.B.F.S. is a paid speaker/presenter for Smith & Nephew and is a paid consultant for Smith & Nephew, Genzyme, and TiGenix. B.A.L. receives royalties from Arthrex and VOT Systems, is a paid consultant for Arthrex, and is a paid speaker/presenter for the Canadian Orthopaedic Association and Smith & Nephew. A.J.K. receives research support from Aesculap/B. Braun, the Arthritis Foundation, Ceterix, and Histogenics; receives royalties from Arthrex; is a paid consultant for Arthrex, Vericel, and DePuy; and has received honoraria from Vericel and the Musculoskeletal Transplant Foundation. AOSSM checks author disclosures against the Open Payments Database (OPD). AOSSM has not conducted an independent investigation on the OPD and disclaims any liability or responsibility relating thereto.

Ethical approval for this study was obtained from the Mayo Clinic (#08-002259).

generated based on the original study group. Values for this group served as a prospective application of the Rapidly Assessed Predictor of Intraoperative Damage (RAPID) score and were not available at the time of original score generation to ensure true prospective testing and validation.

## Imaging

All patients had nonweightbearing anteroposterior (AP), Dunn, and cross-table lateral imaging of the symptomatic hip performed in addition to a centered AP view of the pelvis. Plain radiographs were used to assess Tönnis grade,<sup>28</sup> lateral center-edge angle (LCEA),<sup>19</sup> Tönnis angle,<sup>27</sup> alpha angle,<sup>21</sup> cam morphology,<sup>16</sup> and presence of an ischial spine sign,<sup>13</sup> indicative of acetabular retroversion. Cam morphology was defined as an alpha angle  $>55^\circ$  on the Dunn view. Acetabular dysplasia was defined as an LCEA  $<25^\circ$ . Pincer lesions were defined as an LCEA  $>40^\circ$  or Tönnis angle  $<0^\circ$ .

## Surgical Technique

Surgery was performed by experienced hip arthroscopic surgeons (A.J.K., B.A.L., D.E.H.) in a dedicated operative setting for arthroscopic surgery. Patients were positioned in the modified supine position, and anterolateral and mid-anterior portals were created. Additional use of the anterior, distal anterolateral, and posterolateral portals was employed as needed. Patient positioning and the operative approach have been described in detail previously.<sup>5-8</sup>

Diagnostic arthroscopic surgery was performed to evaluate the labral and acetabular chondral status, which was documented in operative notes as well as on standardized research forms. Damage observed at the time of direct arthroscopic visualization was graded according to the acetabular labrum articular disruption (ALAD) classification system, with grade 1 defined as softening of the cartilage adjacent to the labrum, grade 2 as early peel-back of cartilage, grade 3 as large chondral flaps, and grade 4 as complete loss of cartilage.<sup>14</sup> After diagnostic arthroscopic surgery, subsequent intraoperative procedures included labral repair, cam and pincer resection, microfracture, and chondroplasty, as indicated.

## Statistical Analysis

Descriptive statistics were used to present demographic data with means, standard deviations, and percentages, as appropriate. Patients with high-grade (ALAD grade 3-4) lesions were compared with those without high-grade lesions using the Fisher exact test for proportions and the Mann-Whitney *U* test for nominal values to determine univariate predictors of chondrolabral damage.

A predictive scoring system was generated by entering all variables with a univariate predictive value into a multivariable binary regression model. Subsequently, the ideal set of predictive variables was determined using stepwise regression employing the Akaike information criterion (AIC).<sup>1</sup> Using the AIC, goodness of fit could be quantified and optimized for univariate predictive variables while

penalizing overfitted models that contained more parameters than justified by the data. The AUC was used to evaluate the predictive ability of the RAPID score on the retrospectively and prospectively collected groups. Additionally, analysis of variance was performed to determine whether cartilage damage stratification using the RAPID score was similar between the retrospective and prospective groups.

A priori analysis was used to determine the mean group sample size needed to demonstrate a 15% difference of the proportion of patients with high-grade damage at an alpha of 0.05 and power of 0.95. The resulting estimated mean sample size was 252 per group. Testing was 2-sided, and *P* values  $<.05$  were considered statistically significant. Analyses were conducted in G\*Power 3.1.9.2<sup>9,10</sup> and R 3.4.3 (R Core Team).

## RESULTS

We analyzed 652 primary hip arthroscopic procedures performed between December 2007 and April 2017 on 614 patients (390 female, 224 male). The mean age was  $33.2 \pm 12.5$  years, and the mean body mass index (BMI) was  $26.9 \pm 5.5$  kg/m<sup>2</sup>. Of the study patients, 97% of patients underwent surgery for labral tears (93% repair, 7% debridement), and 61% had concurrent indications for FAI (81% isolated cam, 9% isolated pincer, 10% combined), 2% underwent synovectomy, and 40% had intraoperatively addressed subspine impingement. A total of 298 patients were noted to have ALAD grade 3 to 4 lesions (high grade), and 354 patients were found to have ALAD grade  $\leq 2$  lesions (low grade), meeting the 252 patients per group necessary for a priori power analysis.

Significant differences were observed in age at surgery, sex, BMI, Tönnis grade, and alpha angle between patients with intraoperatively documented high-grade versus low-grade lesions (Table 1). Also, 70.2% of patients in the high-grade group and 44.2% of patients in the low-grade group had cam morphology ( $P < .01$ ), whereas a similar proportion of patients in the high-grade (15.1%) and low-grade (12.8%) groups had pincer morphology ( $P = .51$ ).

Univariate predictors of high-grade chondrolabral damage were subsequently analyzed using binomial models. Age  $\geq 35$  years (OR, 1.96;  $P < .01$ ), male sex (OR, 3.11;  $P < .01$ ), cam morphology (OR, 2.96;  $P < .01$ ), and Tönnis grade 1 to 2 (grade 1: OR, 4.14;  $P < .01$ , and grade 2: OR, 9.29;  $P < .01$ ) were determined to be significant univariate risk factors for intraoperatively documented ALAD grade 3 and 4 lesions (Table 2). While the observed difference of 1.2 kg/m<sup>2</sup> in BMI between the high- and low-grade groups was found to be significant in groupwise comparisons ( $P < .01$ ), this small absolute difference was considered to have a poor clinical discriminatory value.

After univariate analysis, multivariable analysis for the predictors of high-grade chondrolabral damage was performed using stepwise regression with the AIC and assessment of the relative damage risk represented by each predictive factor. The optimal model generated a readily employable, in-clinic scoring system—the RAPID score—which was

TABLE 1  
Demographics by Intraoperatively  
Visualized ALAD Grade<sup>a</sup>

	ALAD Grade		P
	3-4 (n = 298)	0-2 (n = 354)	
ALAD grade, n (%)			<b>&lt;.01</b>
Grade 0	0 (0.0)	89 (25.1)	
Grade 1	0 (0.0)	57 (16.1)	
Grade 2	0 (0.0)	208 (58.8)	
Grade 3	181 (60.7)	0 (0.0)	
Grade 4	117 (39.3)	0 (0.0)	
Age at surgery, y	35.9 ± 11.8	31.0 ± 12.6	<b>&lt;.01</b>
Sex, n (%)			<b>&lt;.01</b>
Female	147 (49.3)	266 (75.1)	
Male	151 (50.7)	88 (24.9)	
Laterality, n (%)			.53
Left	134 (45.0)	150 (42.4)	
Right	164 (55.0)	204 (57.6)	
Body mass index, kg/m <sup>2</sup>	27.5 ± 4.9	26.3 ± 6.0	<b>&lt;.01</b>
Tönnis grade, n (%)			<b>&lt;.01</b>
Grade 0	53 (17.8)	179 (50.6)	
Grade 1	190 (63.8)	155 (43.8)	
Grade 2	55 (18.4)	20 (5.6)	
Grade 3	0 (0.0)	0 (0.0)	
Lateral center-edge angle, deg	30.4 ± 6.5	30.1 ± 5.6	.55
Tönnis angle, deg	6.3 ± 4.3	5.5 ± 4.3	.12
Ischial spine sign, n (%)	122 (40.9)	162 (45.8)	.36
Alpha angle, deg	61.9 ± 11.2	54.2 ± 12.8	<b>&lt;.01</b>

<sup>a</sup>Data are presented as mean ± SD unless otherwise specified. Boldfaced values indicate statistical significance ( $P < .05$ ). ALAD, acetabular labrum articular disruption.

TABLE 2  
Univariate Predictors of High-Grade  
Chondrolabral Damage<sup>a</sup>

	Odds Ratio (95% CI)	P Value
Age		
<35 years	Reference	
≥35 years	1.96 (1.31-2.97)	<b>&lt;.01</b>
Sex		
Female	Reference	
Male	3.11 (2.24-4.34)	<b>&lt;.01</b>
Body mass index		
<30 kg/m <sup>2</sup>	Reference	
≥30 kg/m <sup>2</sup>	1.27 (0.84-1.92)	.26
Tönnis grade		
Grade 0	Reference	
Grade 1	4.14 (2.87-6.05)	<b>&lt;.01</b>
Grade 2	9.29 (5.19-17.20)	<b>&lt;.01</b>
Cam morphology		
Not present	Reference	
Present	2.96 (2.08-4.26)	<b>&lt;.01</b>

<sup>a</sup>Boldfaced values indicate statistical significance ( $P < .05$ ).

based on sex, Tönnis grade, and cam morphology (Table 3). Age and BMI were found to be of poor predictive value and were therefore not included in the final model.

TABLE 3  
RAPID Score for Risk Factors<sup>a</sup>

	Points
Sex	
Female	0
Male	1
Tönnis grade	
Grade 0	0
Grade 1	2
Grade 2	3
Cam morphology	
Not present	0
Present	1
Total	0-5

<sup>a</sup>RAPID, Rapidly Assessed Predictor of Intraoperative Damage.

RAPID scores were calculated and applied to our data set to determine receiver operating characteristics (ROCs). Patients with increasing RAPID scores demonstrated increased rates of intraoperatively visualized ALAD grade 3 and 4 lesions, with a 10.5% risk for patients with 0 points and an 88.0% risk for those with 5 points ( $P < .01$ ) (Figure 2).

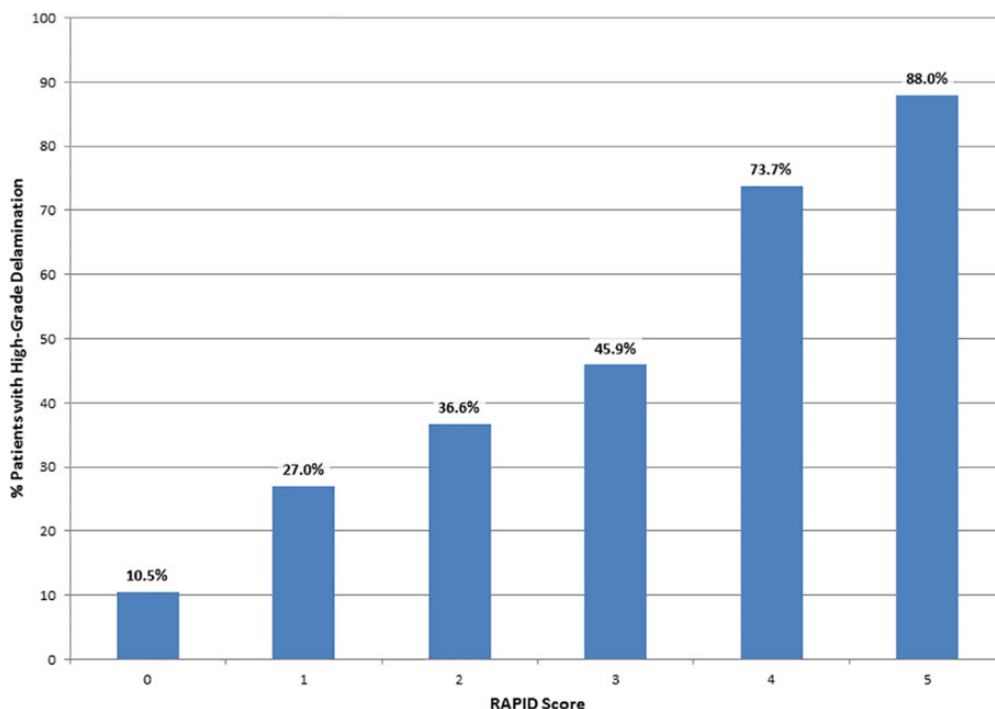
### Prospective Score Verification

After score generation, the RAPID score was validated using a cohort of 167 primary hip arthroscopic procedures performed immediately after the initial study period, from April 2017 to February 2018. Validation data served as a unique set of primary arthroscopic procedures, previously blinded and not viewed or analyzed during the creation of the RAPID score. The observed proportion of patients in the validation group with high-grade damage predicted by the RAPID score was similar to that observed in the original study group from which the RAPID score was generated ( $P = .09$ ) (Figure 3), supporting the generalizability of the score.

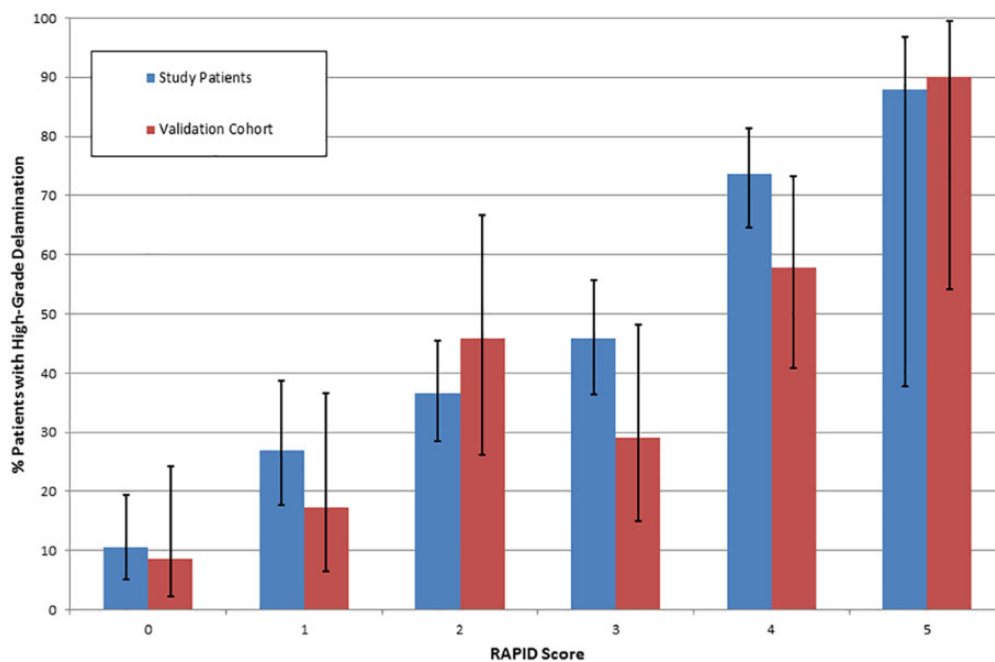
For further analysis of the ROCs of the RAPID score, ROC curves and their associated AUCs were generated for both the study and validation groups (Figure 4). The 2 curves were observed to be similar, with AUCs that differed by 0.003 ( $P = .943$ ), demonstrating that the RAPID score had a similar predictive value for both the study group and the previously blinded data from the validation group.

### DISCUSSION

The preoperative prediction of high-grade chondrolabral damage is of significant clinical value because of consequences for perioperative planning and preparation. The treatment of cartilage defects can potentially require special equipment and preoperative planning for the surgeon and alters the postoperative rehabilitation for the patient. To date, risk factors such as older age, Tönnis grade, and presence of cam deformities have been described on an individual basis. However, there has been no readily available



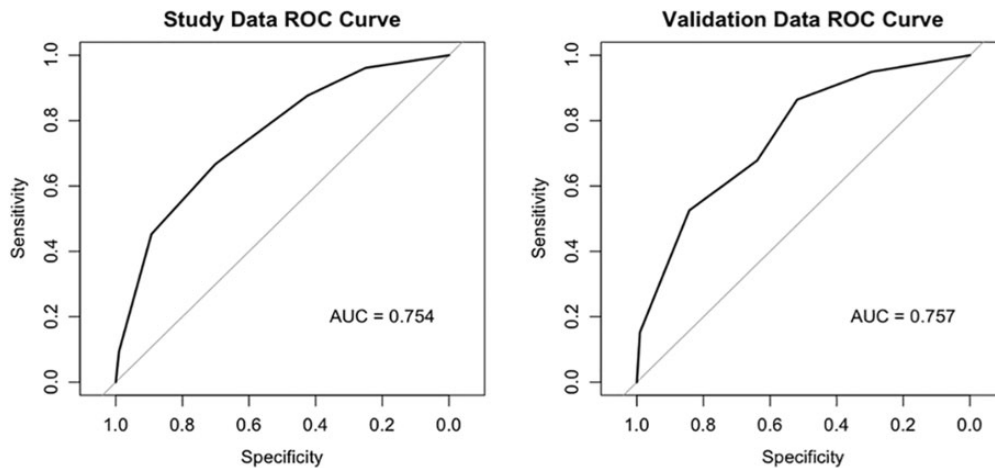
**Figure 2.** Intraoperatively documented acetabular labrum articular disruption (ALAD) grade 3 and 4 lesions by the Rapidly Assessed Predictor of Intraoperative Damage (RAPID) score. Patients were also well stratified, with 29.5% of patients with low-risk RAPID scores of 0 to 1, 44.8% with intermediate-risk RAPID scores of 2 to 3, and 25.6% with high-risk RAPID scores of 4 to 5. The receiver operating characteristics of the RAPID score demonstrated an area under the curve of 0.754.



**Figure 3.** Comparison of observed rates of high-grade damage by the Rapidly Assessed Predictor of Intraoperative Damage (RAPID) score in the validation group with the study group. Error bars = 95% CI.

multivariable system with which to preoperatively stratify patients by the damage risk. Our hypotheses were confirmed in that established risk factors such as sex, cam

morphology, and Tönnis grade predicted damage and that the combination of such factors could be used both retrospectively and prospectively to predict high-grade damage.



**Figure 4.** Receiver operating characteristic (ROC) curves for study data and validation data. AUC, area under the curve.

Our finding that male sex is predictive of damage is consistent with the previous literature, including 64 arthroscopic procedures described by Anderson et al,<sup>2</sup> 1502 patients reported by Suarez-Ahedo et al,<sup>26</sup> and 167 patients in the series by Beaulé et al,<sup>3</sup> all of which provided ORs for male patients ranging between 2.24 and 4.00. While male patients with FAI have been observed to more commonly demonstrate cam morphology as opposed to female patients, both male sex and the presence of a cam lesion were found to be independent predictors of damage in our final multivariable model.

The significance of cam morphology in predicting damage is likely biomechanical in nature.<sup>3,12</sup> It is thought that outside-in shearing contact of the abnormal femoral head-neck junction with the anterosuperior acetabulum during hip flexion and internal rotation is the causative factor for damage.<sup>3</sup> The association between cam morphology and premature arthroplasty is well documented, and a mechanical cause is further supported by published increases in the degenerative risk observed with increasing cam severity.<sup>3,11,20,30</sup> A biomechanical basis is also supported when considering our female population in isolation. Although classically associated with male sex, when we performed a female-only subanalysis, cam morphology conferred a 99% increased risk of high-grade damage ( $P < .01$ ).

While Tönnis grade is a described risk factor for damage, the previous literature has assessed this variable on its own.<sup>4</sup> This limits its clinical utility, as damage is likely the product of the interaction of multiple variables. To our knowledge, Anderson et al<sup>2</sup> have been the only previous group to investigate multivariable predictors of damage. However, their study was not well powered, consisting of only 64 arthroscopic procedures.<sup>2</sup> Only ORs were presented for the factors described, and the operating performance of this model was not reported, significantly limiting its clinical utility. The group also investigated risk scores for damage as they relate to measures of cam and pincer morphology (pistol grip deformity, femoral neck impingement cyst). Neither score attained statistical significance.

By using the AIC, we believe that we have been able to produce a system that maximizes the predictive ability of the data while providing a parsimonious solution with 3 simple variables (sex, Tönnis grade, cam morphology), which can be readily and rapidly assessed in the clinic using history and radiographs. In addition, the use of a validation group is a particular strength of our study. We find it self-evident that a predictive score, based on a study data set, should perform well when applied to the data set from which it was calculated. The observation that the RAPID score, when applied to the previously blinded 2-center validation group, had an AUC statistically equivalent to the original study data greatly strengthens the notion that this score is generalizable. However, further study is warranted for patient populations found outside our health system.

The ROCs of the proposed RAPID score are also worth discussion. The RAPID score was able to predict the progressively increasing risk of intraoperatively observed damage, from 10.5% for a RAPID score of 0 points to 88.0% for a RAPID score of 5 points, providing clinically useful stratification. The observed AUCs of 0.75 and 0.76 for the study and validation groups, respectively, also demonstrate predictive capabilities that are approximately 50% greater than the AUC of 0.52 published for MRA by Rajeev et al.<sup>24</sup> A RAPID score of 5 was found to be highly indicative of damage, with a specificity of 99.1%. While there is certainly room for predictive improvement, the easily assessed nature of the RAPID score, requiring only history and hip radiographs, lends added clinical value to this score.

Examples of the clinical utility of the RAPID score are patients with indeterminate MRI findings or artifacts such as those left by motion or nearby implants. In this case, the RAPID score can serve to better inform nonspecific data, especially given the previously demonstrated limitations of MRI in the femoroacetabular joint. A patient with indeterminate imaging findings but a RAPID score of 4 to 5 (74%-88% risk of high-grade cartilage damage) should be preoperatively counseled for the high likelihood of the performing surgeon's preferred intervention for high-grade

lesions (ie, microfracture that can require partial weight-bearing during the course of recovery or the potential for 2-stage surgery in the setting of autologous chondrocyte implantation [ACI] or matrix-induced ACI). In the case of cell-based procedures such as ACI, high RAPID scores can also serve to prompt case preparation in anticipation of cartilage biopsy for expansion.

The RAPID score is generalizable and able to stratify the cartilage damage risk for patients with varying pathological patterns. A female patient with Tönnis grade 1 and no cam lesion and also a male patient with a cam lesion and Tönnis grade 0 will both have a RAPID score of 2 but appear as quite distinct entities clinically. In our series, of the 95 patients who met the criteria of the female example described above, 38% of them were intraoperatively documented to have high-grade cartilage damage, whereas of the 39 male patients meeting the scenario described above, 33% of them had high-grade damage. This further highlights the value of the easily calculated RAPID score in the clinic. While these patients represent 2 distinct clinical entities, the AIC-optimized RAPID score accurately predicts intraoperatively documented high-grade delamination for both patients, with an estimated risk of 37%, thus providing a simple scoring method to assist clinical decision making.

Our study has important limitations. While variables for the study group were prospectively collected, they were retrospectively analyzed and are dependent on accurate and complete documentation by providers. This is greatly mitigated by the use of standardized forms filled out at the time of arthroscopic intervention. Additionally, while the RAPID score demonstrated satisfactory, comparable ROCs when applied to the validation group, the validation group consisted of 167 patients, or 26% of the original study group, limiting statistical power in comparisons between the score's performance in the 2 groups. Finally, the study presented is the product of 2 high-volume institutions that, aside from performing primary hip arthroscopic surgery, also perform many revision procedures annually. Further research is warranted to ensure the broad applicability of the RAPID score at other institutions, and this is currently underway.

## CONCLUSION

While preoperative MRI has diagnostic value for hip arthroscopic surgery, the RAPID score provides added benefit as a readily employable, in-clinic system for predicting high-grade damage. The discriminatory value of the RAPID score compares favorably with previous MRI and MRA studies. We have found this to be of significant value when evaluating patients, counseling them on likely intraoperative findings and possible alterations in postoperative rehabilitation, and making preparations for hip arthroscopic surgery.

## REFERENCES

1. Akaike H. *Information Theory and an Extension of the Maximum Likelihood Principle*. 2nd International Symposium on Information Theory. Budapest: Akadémiai Kiadó; 1973.

2. Anderson LA, Peters CL, Park BB, Stoddard GJ, Erickson JA, Crim JR. Acetabular cartilage delamination in femoroacetabular impingement: risk factors and magnetic resonance imaging diagnosis. *J Bone Joint Surg Am*. 2009;91(2):305-313.
3. Beaulé PE, Hynes K, Parker G, Kemp KA. Can the alpha angle assessment of cam impingement predict acetabular cartilage delamination? *Clin Orthop Relat Res*. 2012;470(12):3361-3367.
4. Beck M, Leunig M, Parvizi J, Boutier V, Wyss D, Ganz R. Anterior femoroacetabular impingement, part II: midterm results of surgical treatment. *Clin Orthop Relat Res*. 2004;(418):67-73.
5. Camp CL, Reardon PJ, Levy BA, Krych AJ. A simple technique for capsular repair after hip arthroscopy. *Arthrosc Tech*. 2015;4(6):e737-e740.
6. Chow RM, Krych AJ, Levy BA. Arthroscopic acetabular rim resection in the treatment of femoroacetabular impingement. *Arthrosc Tech*. 2013;2(4):e327-e331.
7. Chow RM, Kuzma SA, Krych AJ, Levy BA. Arthroscopic femoral neck osteoplasty in the treatment of femoroacetabular impingement. *Arthrosc Tech*. 2014;3(1):e21-e25.
8. Chow RM, Owens CJ, Krych AJ, Levy BA. Arthroscopic labral repair in the treatment of femoroacetabular impingement. *Arthrosc Tech*. 2013;2(4):e333-e336.
9. Faul F, Erdfelder E, Buchner A, Lang AG. Statistical power analyses using G\*Power 3.1: tests for correlation and regression analyses. *Behav Res Methods*. 2009;41(4):1149-1160.
10. Faul F, Erdfelder E, Lang A-G, Buchner A. G\*Power 3: a flexible statistical power analysis program for the social, behavioral, and biomedical sciences. *Behav Res Methods*. 2007;39(2):175-191.
11. Ganz R, Leunig M, Leunig-Ganz K, Harris WH. The etiology of osteoarthritis of the hip: an integrated mechanical concept. *Clin Orthop Relat Res*. 2008;466(2):264-272.
12. Johnston TL, Schenker ML, Briggs KK, Philippon MJ. Relationship between offset angle alpha and hip chondral injury in femoroacetabular impingement. *Arthroscopy*. 2008;24(6):669-675.
13. Kalberer F, Sierra RJ, Madan SS, Ganz R, Leunig M. Ischial spine projection into the pelvis: a new sign for acetabular retroversion. *Clin Orthop Relat Res*. 2008;466(3):677-683.
14. Kelly BT, Philippon MJ. Arthroscopic hip anatomy. In: Callaghan JJ, Rosenberg AG, Rubash HE, eds. *The Adult Hip*. Philadelphia: Lippincott Williams & Wilkins; 2004:78-79.
15. Krych AJ, Lorich DG, Kelly BT. Treatment of focal osteochondral defects of the acetabulum with osteochondral allograft transplantation. *Orthopedics*. 2011;34(7):e307-e311.
16. Laborie LB, Lehmann TG, Engesaeter IO, Eastwood DM, Engesaeter LB, Rosendahl K. Prevalence of radiographic findings thought to be associated with femoroacetabular impingement in a population-based cohort of 2081 healthy young adults. *Radiology*. 2011;260(2):494-502.
17. Mamisch TC, Zilkens C, Siebenrock KA, Bittersohl B, Kim YJ, Werlen S. MRI of hip osteoarthritis and implications for surgery. *Magn Reson Imaging Clin N Am*. 2010;18(1):111-120.
18. Mella C, Nunez A, Villalon I. Treatment of acetabular chondral lesions with microfracture technique. *Sicot J*. 2017;3:45.
19. Murphy SB, Kijewski PK, Millis MB, Harless A. Acetabular dysplasia in the adolescent and young adult. *Clin Orthop Relat Res*. 1990;(261):214-223.
20. Nepple JJ, Carlisle JC, Nunley RM, Clohisy JC. Clinical and radiographic predictors of intra-articular hip disease in arthroscopy. *Am J Sports Med*. 2011;39(2):296-303.
21. Notzli HP, Wyss TF, Stoecklin CH, Schmid MR, Treiber K, Hodler J. The contour of the femoral head-neck junction as a predictor for the risk of anterior impingement. *J Bone Joint Surg Br*. 2002;84(4):556-560.
22. Pfirrmann CW, Duc SR, Zanetti M, Dora C, Hodler J. MR arthrography of acetabular cartilage delamination in femoroacetabular cam impingement. *Radiology*. 2008;249(1):236-241.
23. Philippon MJ, Schenker ML, Briggs KK, Maxwell RB. Can microfracture produce repair tissue in acetabular chondral defects? *Arthroscopy*. 2008;24(1):46-50.

24. Rajeev A, Tuinebreijer W, Mohamed A, Newby M. The validity and accuracy of MRI arthrogram in the assessment of painful articular disorders of the hip. *Eur J Orthop Surg Traumatol*. 2018;28(1):71-77.
25. Spencer-Gardner L, Krych AJ, Kelly BT. Surgical technique: osteochondral autograft transfer and osteochondral allograft transplant for preservation of the femoral head and acetabulum. In: Nho SJ, Leunig M, Larson CM, Bedi A, Kelly BT, eds. *Hip Arthroscopy and Hip Joint Preservation Surgery*. 1st ed. New York: Springer; 2015:1129-1141.
26. Suarez-Ahedo C, Gui C, Rabe SM, Chandrasekaran S, Lodhia P, Domb BG. Acetabular chondral lesions in hip arthroscopy: relationships between grade, topography, and demographics. *Am J Sports Med*. 2017;45(11):2501-2506.
27. Tönnis D. *Congenital Dysplasia and Dislocation of the Hip in Children and Adults*. Berlin: Springer; 1987.
28. Tönnis D, Heinecke A. Acetabular and femoral anteversion: relationship with osteoarthritis of the hip. *J Bone Joint Surg Am*. 1999;81(12):1747-1770.
29. Uchida S, Utsunomiya H, Mori T, et al. Clinical and radiographic predictors for worsened clinical outcomes after hip arthroscopic labral preservation and capsular closure in developmental dysplasia of the hip. *Am J Sports Med*. 2016;44(1):28-38.
30. Wyles CC, Heidenreich MJ, Jeng J, Larson DR, Trousdale RT, Sierra RJ. The John Charnley Award: redefining the natural history of osteoarthritis in patients with hip dysplasia and impingement. *Clin Orthop Relat Res*. 2017;475(2):336-350.